38 Folliculitis, Follicular Occlusion Tetrad, and Other Follicular Disorders

Jennifer L. Hsiao, Vivian Y. Shi and Kieron S. Leslie

Chapter Contents

Superficial Folliculitis 622
Disorders of Follicular Keratinization 629
Trichostasis Spinulosa 631
Viral-Associated Trichodysplasia Spinulosa 631
Deep Folliculitis 632
Follicular Occlusion Tetrad. 635

INTRODUCTION

This chapter reviews both superficial and deep forms of folliculitis as well as disorders of follicular keratinization. Examples of superficial folliculitis include those due to *Staphylococcus aureus* or *Pseudomonas aeruginosa* infections, whereas acne keloidalis and pseudofolliculitis barbae are examples of deep forms. Hidradenitis suppurativa, a major entity within the follicular occlusion tetrad, is increasingly being recognized as a systemic inflammatory disorder. The disorders of follicular keratinization represent a varied group of dermatoses that have in common prominent keratotic follicular plugs. Some of these disorders are reviewed in other chapters, e.g. lichen planopilaris, pityriasis rubra pilaris (PRP) and keratosis pilaris, while others are discussed here, e.g. lichen spinulosus and erythromelanosis follicularis faciei.

SUPERFICIAL FOLLICULITIS

Synonym: ■ Impetigo of Bockhart

Key features

- Folliculocentric papules and pustules, often arising on an erythematous base
- Favors areas with terminal hairs and a greater density of sebaceous glands, such as the scalp, beard, and upper trunk, as well as the buttocks and lower extremities
- Bacterial culture of pustular contents most commonly reveals normal flora, followed by *Staphylococcus aureus*
- Treatment depends on the particular type of folliculitis

Introduction

Folliculitis is a very common disorder characterized by follicular papules and pustules with varying degrees of inflammation. It occurs most commonly in adolescents and adults. Folliculitis can be secondary to a wide range of infectious agents, or be induced by irritants or drugs (Fig. 38.1). While potential pathogens include bacteria, fungi, viruses, and parasites, culture of pustular contents most commonly reveals normal flora ("culture-negative"), followed by *Staphylococcus aureus*.

Clinical features

Follicular pustules are usually accompanied by an erythematous rim (Fig. 38.2). If no pustules are present, follicular-based erythematous papules or a superimposed collarette of scale serve as clues to the diagnosis. Comedones are not typically seen unless the patient also has acne vulgaris. Lesions may be pruritic or even tender or painful. Generalized pruritus can accompany more widespread disease.

Folliculitis occurs most commonly in the head and neck region (especially the scalp and beard area), upper trunk, buttocks, and legs, as well as in the axillae and groin (Fig. 38.3). It favors areas that are occluded and/or have a greater density of terminal hairs. In addition, shaving can predispose to folliculitis.

Pathology

The early inflammatory infiltrate consists primarily of perifollicular neutrophils with extension into the follicular epithelium and follicular ostium. This is soon followed by an admixture with lymphocytes and macrophages. Late-stage changes include follicular rupture and a granulomatous response. Deeper inflammatory reactions may lead to scarring alopecia.

Tissue Gram stain may reveal pathogenic organisms. Occasionally, cytopathic changes due to herpes simplex or zoster viral infections are seen within the follicular epithelium (see Ch. 80). In dermatophyte infections, hyphae can be seen within hair shafts or in the follicular ostium (see Fig. 77.13G). The presence of *Demodex* organisms (see Fig. 38.5H) or yeast forms requires clinicopathologic correlation as they are commensal organisms.

Differential diagnosis

In addition to the various forms of folliculitis listed in Table 38.1, the differential diagnosis also includes acne vulgaris, pseudofolliculitis barbae, and occasionally, rosacea. Dermoscopy can assist in confirming that the papules are folliculocentric, allowing distinction from other disorders such as Grover disease. Microscopic examination of follicular contents may provide a clue to the type of folliculitis as can microbial cultures and histologic examination. In patients who are confined to bed, folliculitis may develop predominantly on the posterior trunk and thus needs to be distinguished from other disorders exacerbated by occlusion including Grover disease, miliaria rubra, and cutaneous candidiasis.

Treatment

Superficial folliculitis may be self-limited, especially if exacerbating factors are addressed. The treatment chosen depends upon the culture results and severity (see Chs. 74 & 127). For patients whose cultures fail to demonstrate a pathogenic microbe, the treatments, as in acne, include topical benzoyl peroxide, topical antibiotics, and oral antibiotics (e.g. doxycycline), with the anti-inflammatory properties of these antibiotics likely playing a role. This should be combined with measures to reduce overhydration of the skin, occlusion, and irritation.

Malassezia (*Pityrosporum*) Folliculitis

Malassezia (*Pityrosporum*) folliculitis is most commonly associated with *M. globosa*, *M. furfur*, and *M. sympodialis* (see Ch. 77). These commensal yeasts favor sebaceous-rich skin and typically become pathogenic under certain favorable conditions – a warm, humid climate, excessive sebum production or sweating, occlusion from emollients, use of systemic antibiotics, and immunosuppression. Yeast lipases can cleave sebaceous triglycerides, with the resultant free fatty acids serving as potential irritants and proinflammatory mediators.

Downloaded for Anonymous User (n/a) at Egyptian Knowledge Bank from ClinicalKey.com by Elsevier on March 10, 2024. For personal use only. No other uses without permission. Copyright ©2024. Elsevier Inc. All rights reserved.

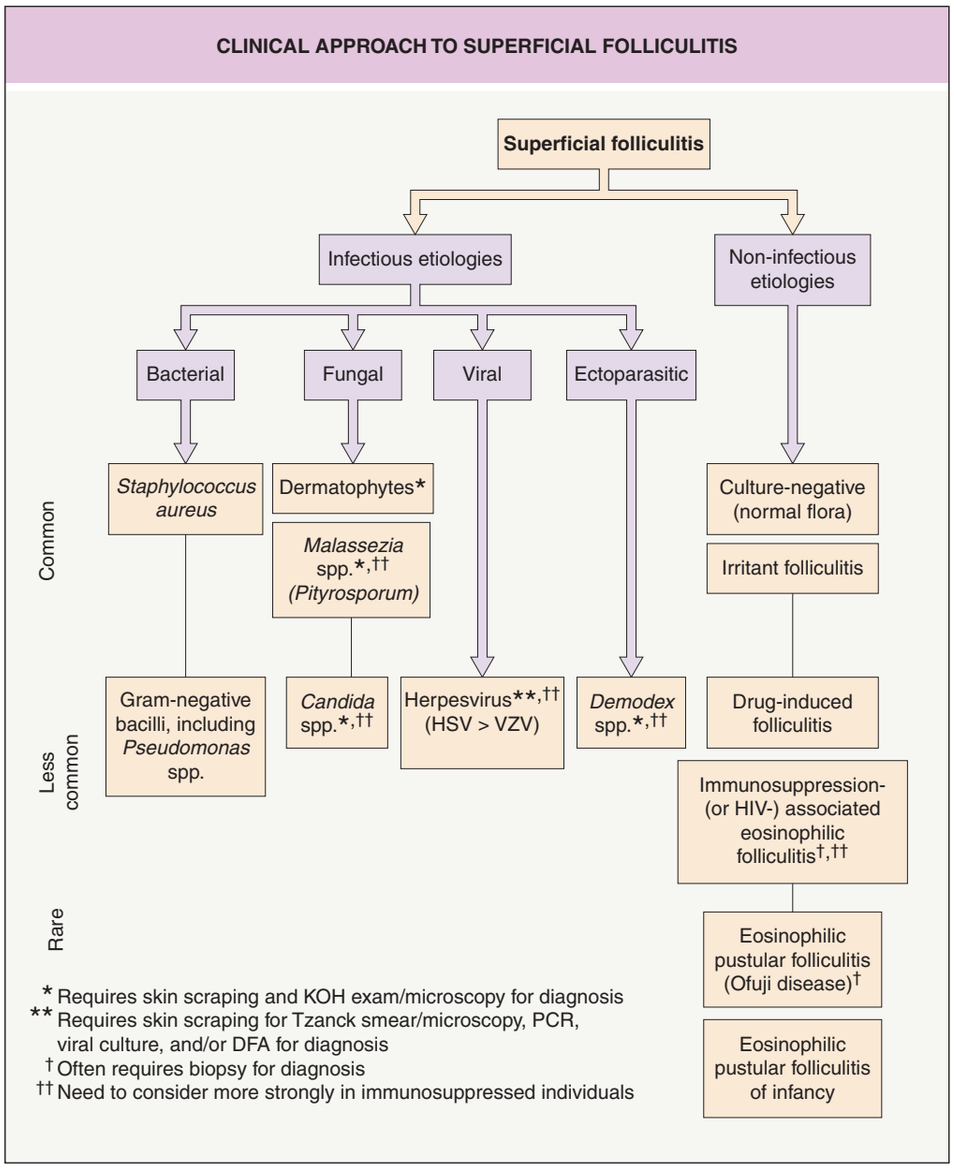

Fig. 38.1 Clinical approach to superficial folliculitis. Edematous lesions of folliculitis are most suggestive of eosinophilic folliculitis, *Demodex* folliculitis, and *Pseudomonas* "hot tub" folliculitis. See Table 38.1 for medications that can cause drug-induced folliculitis. *Courtesy Jean L. Bolognia, MD.*



Fig. 38.2 Folliculitis (culture-negative). Follicular pustules with an erythematous rim on the buttocks of a 3-year-old who wore "pull-ups" at night. *Courtesy Julie V. Schaffer, MD.*

Malassezia (Pityrosporum) folliculitis presents as multiple monomorphic, oftentimes pruritic, small follicular papules and occasionally pustules. A central keratin plug may be present. Lesions favor the upper trunk of teenagers and young adults (Fig. 38.5D), but may also appear on the shoulders, neck, and face (especially the forehead and anterior hairline). Diagnosis can be established via KOH examination of follicular contents, which demonstrates spherical yeast forms. In addition to addressing predisposing factors, treatment options include topical antifungal creams or lotions and selenium sulfide shampoo. For more widespread disease or topical therapy failure, oral fluconazole can be used, e.g. 150–300 mg once weekly for 1–2 months.

Eosinophilic Folliculitis

Three major forms of eosinophilic folliculitis have been described – eosinophilic pustular folliculitis (Ofuji disease), immunosuppression (or HIV)-associated eosinophilic pustular folliculitis, and eosinophilic pustular folliculitis of infancy.

Eosinophilic pustular folliculitis

Synonyms: ▪ Ofuji disease ▪ Eosinophilic folliculitis

Downloaded for Anonymous User (n/a) at Egyptian Knowledge Bank from ClinicalKey.com by Elsevier on March 10, 2024. For personal use only. No other uses without permission. Copyright ©2024. Elsevier Inc. All rights reserved.



Fig. 38.3 Folliculitis of the axilla and beard area due to *Staphylococcus aureus*. **A** Numerous follicular pustules with an erythematous rim emanating from the axillary vault. **B** Discrete papulopustules are seen posteriorly, while centrally there is deeper involvement with plaque formation (sycosis barbae). *A, Courtesy Kalman Watsky, MD.*

Key features

- Follicular papulopustules as well as erythematous patches and plaques with superimposed coalescent pustules; central clearing leads to figurate lesions
- Most commonly involves the face, followed by the upper extremities and trunk
- Often moderate to severe pruritus
- Recurrent crops of lesions typically involute over 7–10 days
- Peripheral blood eosinophilia also present
- Histologically, intrafollicular and perifollicular eosinophil-rich infiltrates

Introduction

Eosinophilic pustular folliculitis is characterized by recurrent episodes of eruptive, intensely pruritic, follicular papulopustules, often in association with peripheral blood eosinophilia. It typically affects "acne-prone" areas of the body such as the face, back, and extensor surface of the arms[1]. To date, this disorder has not been associated with systemic disease.

History

In 1965, Ise and Ofuji[2] were the first to report a patient who had repeated episodes of follicular pustules on the face and back along with peripheral blood eosinophilia. Of note, this disorder is not to be confused with papuloerythroderma of Ofuji (see Ch. 26).

Epidemiology

Eosinophilic pustular folliculitis is a relatively rare entity, with most of the cases reported from Japan. The majority of patients are Asian adults, with an average age of onset between 20 and 40 years. The ratio of men to women is ~5:1 amongst Japanese patients and ~1:1.6 in Singapore[3]. There have been occasional reports of eosinophilic pustular folliculitis in children, often with clinical features similar to the infantile form (see below).

Pathogenesis

The etiology of eosinophilic pustular folliculitis remains unclear. Proposed mechanisms include hypersensitivity reactions to various antigenic stimuli (e.g. infectious agents, medications), Th2 pathway skewing, and immune dysfunction[4]. The presence of $CD163^+$ M2 macrophages, which play a role in parasitic infections, as well as $pSTAT6^+$ and IL-10-producing cells within lesional skin point to Th2 polarization[5]. Via GATA3, STAT6 in concert with STAT5 induces Th2 cells to secrete IL-4, IL-5, and IL-13; these cytokines are known to play a key role in the recruitment of eosinophils. In addition, elevated serum levels of the chemokine TARC have been observed in eosinophilic pustular folliculitis[6], as in other disorders with peripheral eosinophilia such as drug reaction with eosinophilia and systemic symptoms (DRESS). Prostaglandin D2 may also play a role in the activation of pilosebaceous units and recruitment of eosinophils. This provides a possible explanation for the therapeutic response to indomethacin, a COX inhibitor that inhibits prostaglandin synthesis[7].

Clinical features

Recurrent crops of intensely pruritic, grouped, follicular pustules and papulopustules erupt in a rapid fashion. In addition, there may be erythematous patches and plaques with superimposed coalescent pustules; central clearing and centrifugal extension produce annular and figurate lesions. Typically, areas with "sebaceous" follicles, such as the face, back, and extensor surface of the arms, are affected. However, the digits, palms, and soles may be involved, proving that not all lesions are follicular. Lesions last 7–10 days and tend to relapse every 3–4 weeks. Because this disorder most commonly occurs in individuals with darker skin phototypes, postinflammatory hyperpigmentation is a common finding. The patients have no accompanying systemic symptoms.

Pathology

Involved follicles show spongiosis with exocytosis of eosinophils ("eosinophilic spongiosis"), admixed with variable numbers of lymphocytes and neutrophils. Micropustular aggregation develops, followed by the hallmark finding of infundibular eosinophilic pustules[8]. While these findings are particularly prominent in the infundibular region, they are accompanied by perifollicular inflammatory infiltrates with a similar cellular composition.

Differential diagnosis

Clinically, some of the lesions may resemble other forms of superficial folliculitis (see previous section), acneiform eruptions, and other figurate erythemas, in particular eosinophilic annular erythema, hydroxychloroquine-induced generalized pustular figurate erythema, and pustular psoriasis. However, the explosive crops, annular plaques with central clearing, intense pruritus, peripheral blood eosinophilia, and histologic findings typically enable differentiation from clinically similar entities. Rarely, early eosinophilic pustular folliculitis may have a symmetric, butterfly rash-like presentation that resembles acute cutaneous lupus erythematosus.

Treatment

Potent topical corticosteroids, tacrolimus ointment, topical indomethacin[9], and oral antihistamines can be prescribed for the associated pruritus as well as for mild localized disease. Oral indomethacin (50 mg/day) is recommended as first-line systemic therapy. Second-line therapies include UVB phototherapy, oral minocycline (100 mg twice daily), oral dapsone (100 to 200 mg/day for ≥2 weeks), systemic corticosteroids, and colchicine (0.6 mg twice daily). Oral cyclosporine or isotretinoin may be considered in patients with refractory disease.

Downloaded for Anonymous User (n/a) at Egyptian Knowledge Bank from ClinicalKey.com by Elsevier on March 10, 2024. For personal use only. No other uses without permission. Copyright ©2024. Elsevier Inc. All rights reserved.

LESS COMMON SPECIFIC FORMS OF FOLLICULITIS		
Etiology/risk factors	**Clinical features**	**Therapy**
Irritant folliculitis		
Usually occurs following the application of irritating topical medications (e.g. tar preparations), topical keratolytics, or chemical peels Exacerbated by application in a direction opposite that of hair growth	• Follicular papules and pustules in the sites of application or exposure to irritant • Favors areas with terminal hairs	• Discontinue inciting topical agent • Apply medications in the same direction as hair growth • Topical corticosteroids
Gram-negative folliculitis		
Due primarily to *Klebsiella, Escherichia coli, Enterobacter* and *Proteus* spp. Usually seen in patients with acne vulgaris receiving long-term antibiotic therapy Can occur in setting of primary immunodeficiency (e.g. HIV) or α-1-antitrypsin deficiency	• Papules and pustules in the facial T-zone and in a perinasal distribution • Adult men with oily skin • Organisms isolated from nares as well as cutaneous lesions	• Topical: gentamicin, benzoyl peroxide • Systemic: quinolones (e.g. ciprofloxacin), ampicillin or trimethoprim/sulfamethoxazole • If severe or recurrent: isotretinoin, 0.5–1 mg/kg/day for up to 16 weeks
Hot tub folliculitis, due primarily to *Pseudomonas aeruginosa* Follows exposure to contaminated water in hot tubs or whirlpools > swimming pools	• Typically appear 12–48 hours after exposure • Edematous, pink to red follicular papules and pustules, primarily on the trunk > extremities (Fig. 38.4) • Often pruritic and resolves spontaneously in immunocompetent patients • May lead to serious illness in immunocompromised patients (e.g. ecthyma gangrenosum)	• Generally self-limited; can use antibacterial soap • If severe or immunocompromised host: ciprofloxacin, 500 mg po twice daily for 7–14 days • Prevention: adequate chlorine levels, e.g. 2–4 mg/L for swimming pools, 3–5 mg/L for hot tubs, and pH of 7.2–7.4
Dermatophyte folliculitis		
Tinea barbae – usually due to zoophilic dermatophytes *Trichophyton mentagrophytes* or *T. verrucosum* Risk factors include occupational or recreational exposure to infected animals	• Inflammatory papules and pustules in the beard area more often than the mustache, with crusting • Loosened hairs can be removed without pain	• Topical antifungals (may be ineffective) • Terbinafine, 250 mg/day po for 2–4 weeks • Microsized or ultramicrosized griseofulvin, 500–1000 mg/day or 500–750 mg/day po, respectively, for 4–8 weeks • Fluconazole, 150 mg po once weekly for 2–4 weeks • Itraconazole, 200 mg po twice daily for 1 week per month, for 2 pulses
Majocchi granuloma – a follicular infection most commonly due to *T. rubrum* Can have perifollicular granulomatous inflammation Risk factors include shaving of legs, use of potent topical corticosteroids, occlusion, and immunosuppression	• Follicular pustules and follicular papules or nodules (Fig. 38.5A-C), most often located on the lower extremities • Often arises within expanding lesions of tinea corporis, cruris or pedis • Also arises in the setting of tinea incognito where scale is absent but KOH examination is floridly positive	• Oral antifungal medications recommended, with treatment regimens similar to tinea barbae (see above) • Immunosuppressed patients may need a longer course of therapy
***Candida* folliculitis**		
Most commonly caused by *Candida albicans* Predisposing factors include diabetes, obesity, immunosuppression, intravenous drug use, recent use of systemic corticosteroids or broad-spectrum antibiotics, occlusion, heat and humidity	• Pruritic satellite pustules surrounding areas of intertriginous candidiasis • Facial lesions may mimic tinea barbae or acne rosacea • KOH examination: budding yeasts and pseudohyphae	• Prevent skin-to-skin contact in intertriginous areas • If possible, discontinue antibiotics and/or corticosteroid therapy • Mild to moderate disease: topical antifungals • Recalcitrant or severe disease: fluconazole 150 mg po once weekly for 4 weeks, or 100 mg po daily for 1 week then every other day for 1 month
Herpetic folliculitis		
Herpetic sycosis is usually seen in men with a history of recurrent localized facial herpes simplex infection who shave with a blade razor Widespread or unusual presentations of herpes simplex folliculitis may be seen in HIV-infected or otherwise immunosuppressed individuals as well as in the setting of eczema herpeticum Often seen in herpes zoster	• Rapid development of individual and grouped follicular pustules and vesicles on an erythematous base • If due to herpes simplex, occurs most commonly on the face • When due to herpes zoster, can be associated with entities in Table 80.7 • A Tzanck smear or biopsy reveals multinucleated giant cells • Positive PCR or DFA	• Acyclovir 200 mg po 5 times per day for 5–10 days • Famciclovir 250–500 mg po three times per day for 5–10 days • Valacyclovir 500 mg po three times per day for 5–10 days • IV acyclovir 5–10 mg/kg every 8 hours can be used for extensive disease, especially in the context of immunosuppression
***Demodex* folliculitis (demodicosis)**		
Most commonly caused by *Demodex folliculorum* and *D. brevis* May be associated with immunosuppression	• Erythematous follicular papules and pustules on the face, especially the nose, and neck; may have a background of diffuse erythema (Fig. 38.5E,F) • Less common presentations include blepharitis, madarosis, and demodectic frost of the ear • Skin scrapings reveal numerous *Demodex* mites (Fig. 38.5G)	• Topical: ivermectin 1% cream, metronidazole 1% cream, permethrin 1% or 5% cream, sodium sulfacetamide 10%/sulfur 5% lotion, crotamiton 10% cream or lotion, benzyl benzoate 10% lotion • Systemic: ivermectin 200 mcg/kg po once weekly for 1–2 weeks, metronidazole 250 mg po TID for 7–14 days, ornidazole*, isotretinoin

Table 38.1 Less common specific forms of folliculitis.

Downloaded for Anonymous User (n/a) at Egyptian Knowledge Bank from ClinicalKey.com by Elsevier on March 10, 2024. For personal use only. No other uses without permission. Copyright ©2024. Elsevier Inc. All rights reserved.

LESS COMMON SPECIFIC FORMS OF FOLLICULITIS		
Etiology/risk factors	**Clinical features**	**Therapy**
Drug-induced folliculitis (acneiform eruption)		
Most common in acne-prone patients and age groups Corticosteroids, androgenic hormones, inhibitors of EGFR, BRAF, MEK and HER2, anticonvulsants, bromides, iodides, isoniazid, lithium, sirolimus, vitamin B_{12} supplementation Can develop within 2 weeks of starting the offending agent, but the risk is often proportional to the dose and duration of therapy	• Acute eruption of monomorphic erythematous follicular papules and pustules on the face, trunk, shoulders, and upper arms (see Figs. 21.21B & 36.13) • Multiple papulopustules of the face and scalp, sometimes admixed with scale-crust (see Figs. 21.21C & 36.15) • Unlike acne vulgaris, comedones are rarely present (with the exception of androgens)	• Discontinue or lower the dose of the offending drug, if possible • Topical: benzoyl peroxide, clindamycin, erythromycin, retinoids; corticosteroids (EGFR-induced eruptions; see Ch. 21) • Systemic: tetracycline, doxycycline, minocycline; if secondarily infected, antibiotic based upon culture; isotretinoin
Necrotizing infundibular crystalline folliculitis		
Yeasts (e.g. *Malassezia* spp.) and Gram-positive bacteria (e.g. *Cutibacterium acnes*) in affected follicles	• Waxy folliculocentric papules with predilection for the forehead, neck, and back • Birefringent, filamentous, crystalline deposits within follicular ostia • Thought to be microbial-induced crystallization of sebum	• Topical or systemic antimycotics • Topical or systemic antibiotics
Actinic folliculitis		
Seasonal, possibly caused by ultraviolet A radiation and local heat Follows initial summer sun exposure	• Monomorphic follicular papules and pustules in sun-exposed sites – face, neck, upper trunk, and arms • Arises 4–30 hours after sunlight exposure	• Sun avoidance as sunscreens will not prevent lesion formation • Usually resolution within 5–10 days after discontinuation of sunlight exposure • Topical mid-potency corticosteroids or retinoids • Isotretinoin 0.35–0.5 mg/kg/day for 3–6 months if severe
*Not an FDA-approved drug.		

Table 38.1 Less common specific forms of folliculitis. DFA, direct immunofluorescence assay; EGFR, epidermal growth factor receptor; HER2, human epidermal growth factor receptor 2; HIV, human immunodeficiency virus; MEK, mitogen-activated protein kinase kinase (MAPK); mTOR, mechanistic target of rapamycin; PCR, polymerase chain reaction.

Immunosuppression-associated eosinophilic pustular folliculitis

Synonyms: ■ AIDS-associated eosinophilic folliculitis ■ HIV-associated eosinophilic folliculitis ■ Immunosuppression-associated eosinophilic folliculitis

Key features

- Markedly pruritic follicular papules, urticarial and/or pustular, that favor the face, scalp, and upper trunk
- Occurs in the setting of immunosuppression, including from HIV infection or systemic medications and following allogeneic hematopoietic stem cell transplantation
- In HIV-infected patients, the CD4 count is usually <200 cells/mm^3; it may also be a manifestation of IRIS (immune reconstitution inflammatory syndrome)
- Histopathologic findings, consisting of spongiosis and exocytosis of eosinophils and lymphocytes into the follicular epithelium, are similar to those in other types of eosinophilic pustular folliculitis

Introduction and history

A pruritic papular eruption with histologic features similar to eosinophilic pustular folliculitis (Ofuji disease) was originally described in HIV-infected patients, many of whom fulfilled the criteria for AIDS. Eosinophilic folliculitis has subsequently been observed in patients with myeloproliferative disorders, as well as in those who have undergone allogeneic hematopoietic stem cell transplantation; hence, the use of the term *immunosuppression-associated eosinophilic pustular folliculitis*. However, in contrast to Ofuji disease, coalescent pustules and figurate lesions would be unusual, and the individual lesions tend to be more persistent.



Fig. 38.4 *Pseudomonas* "hot tub" folliculitis. Edematous follicular papules of the flank that began to develop 2–3 days following the use of a hot tub. *Courtesy Kalman Watsky, MD.*

Epidemiology

Although the early descriptions of HIV-associated eosinophilic folliculitis were in men, it can also occur in women[10]. The majority of these patients are 20–50 years of age, while there is a wide range of ages in non-HIV-related cases, reflecting the age of onset of associated hematologic malignancies. Development of HIV-associated eosinophilic folliculitis correlates with a low CD4 count (in particular <200/mm^3 or CD4:CD8 ratio <0.5) and clinical improvement has been observed as the CD4 count rises due to antiretroviral therapy (ART). However, there are instances where eosinophilic folliculitis develops within 3 to 6 months of initiating ART, implying an association with the immune reconstitution inflammatory syndrome (IRIS; see Ch. 78).

Downloaded for Anonymous User (n/a) at Egyptian Knowledge Bank from ClinicalKey.com by Elsevier on March 10, 2024. For personal use only. No other uses without permission. Copyright ©2024. Elsevier Inc. All rights reserved.

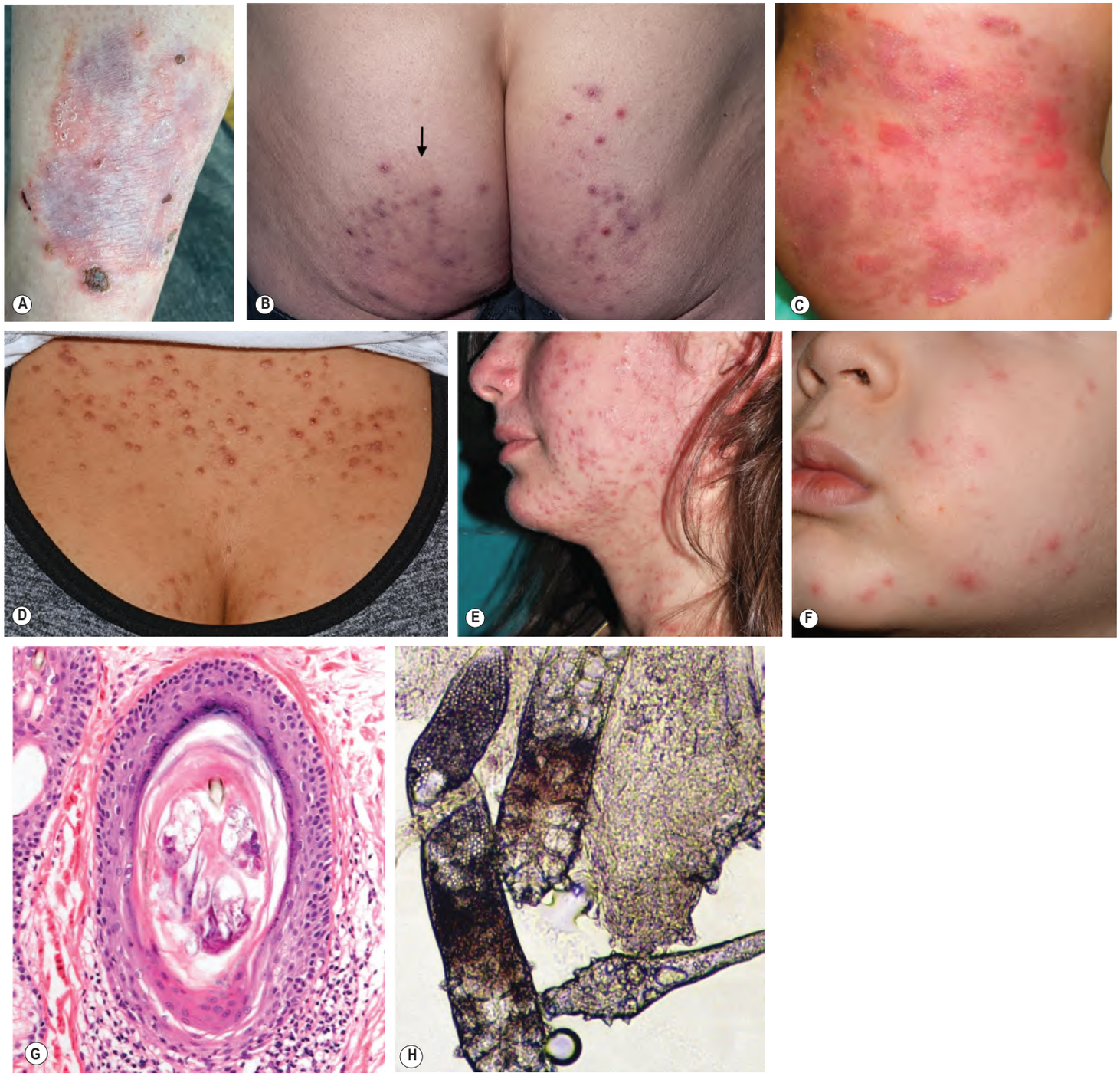

Fig. 38.5 Folliculitis – fungal and ectoparasitic. A Dermatophyte folliculitis of the shin within a lesion of tinea corporis; the lower leg is a common location. **B** Dermatophyte folliculitis on the buttocks arising within subtle tinea corporis (arrow). A few papulopustules admixed with both erythematous papules that have a collarette of scale and healed lesions. **C** Dermatophyte folliculitis with firm follicular papules in the setting of extensive tinea corporis. **D** *Malassezia* (*Pityrosporum*) folliculitis of the chest with multiple pruritic, monomorphic follicular papules; KOH examination of the follicular contents showed abundant yeast. **E** Numerous papules and papulopustules of *Demodex* folliculitis on the face and neck; note the edematous nature of several of the lesions. **F** Facial papules and papulopustules of *Demodex* folliculitis in a child with acute lymphocytic leukemia. **G** Histopathologic features of *Demodex* folliculitis with several organisms within the follicular ostium. **H** Microscopic findings of follicular contents obtained via scraping of *Demodex* folliculitis. *A, Courtesy Karynne O. Duncan, MD; B, Courtesy Edward Cowen, MD; D,F, Courtesy Julie V. Schaffer, MD; E, Courtesy Angela Hernández-Martin; G, Courtesy Lorenzo Cerroni, MD.*

Pathogenesis

Little is known about the exact pathogenesis of immunosuppression-associated eosinophilic folliculitis. However, as in other eosinophilic diseases, a Th2 immune response has been implicated. In patients with AIDS, elevated levels of interleukin (IL)-4, IL-5, RANTES (CCL5), and eotaxin (CCL11) mRNA were detected within lesional skin (see Ch. 26)[11]. Elevated serum levels of three additional chemokines, CCL17, CCL26 (eotaxin-3) and CCL27, have also been observed in patients with HIV-associated eosinophilic folliculitis[12].

Clinical features

Immunosuppression-associated eosinophilic folliculitis is characterized by recurrent, intensely pruritic papules and pustules in acne-prone areas, i.e. the face, scalp, and upper trunk (Fig. 38.6A). The papules are

Downloaded for Anonymous User (n/a) at Egyptian Knowledge Bank from ClinicalKey.com by Elsevier on March 10, 2024. For personal use only. No other uses without permission. Copyright ©2024. Elsevier Inc. All rights reserved.



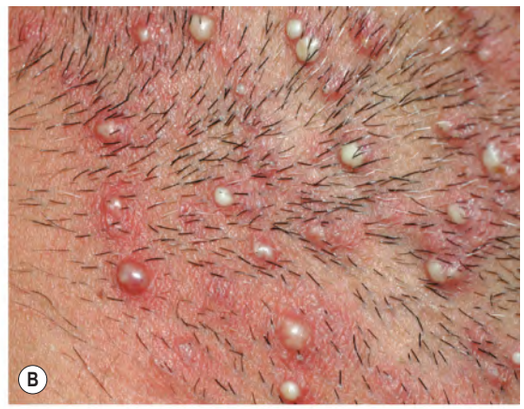

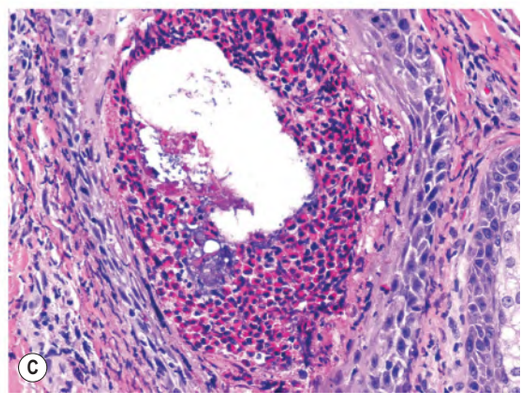

Fig. 38.6 Immunosuppression-associated eosinophilic folliculitis. **A** Multiple follicular papules on the anterior trunk in a patient who had received an allogeneic hematopoietic stem cell transplant. Note the edematous nature of some of the lesions. Very few pustules were present. **B** In some patients, multiple follicular pustules are seen. **C** A dilated hair follicle with an intrafollicular collection of eosinophils; a few eosinophils are also present within the follicular epithelium. *A, Courtesy Dennis Cooper, MD; B,C, Courtesy Luis Requena, MD.*

often slightly edematous and pustules may or may not be present (Fig. 38.6B). The associated pruritus is often intense. Some patients may also have lymphopenia.

Pathology
The histologic features are similar to those of Ofuji disease (see above; Fig. 38.6C)

Differential diagnosis
The differential diagnosis includes more common causes of folliculitis (see above) as well as the entities outlined in Table 38.1, especially *Demodex* folliculitis. Microscopic examination of follicular contents as well as performance of a biopsy may be necessary to establish the diagnosis (see Fig. 38.1). Additional disorders to consider, especially when there are no pustules and it is uncertain if lesions are follicular-based, are HIV-associated pruritic papular eruption[13], papular dermatitis, or arthropod bites and other causes of a "dermal hypersensitivity reaction".

Treatment
Although HIV-associated eosinophilic folliculitis can be refractory to treatment, institution of ART often leads to improvement; however, a flare may be seen in the setting of IRIS. In the latter patients, ART should be continued as the IRIS-related disease activity gradually subsides. Temporary interruption of ART is not required if eosinophilic folliculitis is the primary manifestation of IRIS.

For all patients, oral and topical antipruritics in combination with topical corticosteroids can be tried. Additional therapies include topical tacrolimus, topical permethrin, oral itraconazole (200–400 mg daily), oral metronidazole (250 mg three times daily), other oral antibiotics, and isotretinoin (0.5–1 mg/kg/day)[14]. UVB phototherapy may be tried when the folliculitis is extensive or recalcitrant.

Eosinophilic pustular folliculitis of infancy

Synonyms: ■ Eosinophilic pustular folliculitis in infancy ■ Infantile eosinophilic pustular folliculitis ■ Neonatal eosinophilic pustular folliculitis ■ Eosinophilic pustular folliculitis in childhood ■ Eosinophilic pustulosis (of the scalp) in childhood

Eosinophilic pustular folliculitis of infancy is a rare, self-limiting disorder (see Ch. 34). It presents as pruritic, follicular-based pustules and vesiculopustules with an erythematous rim. The scalp is the most common site of involvement; less often lesions are seen on the face and neck, followed in frequency by the upper trunk and extremities. A cyclical course, with recurrences at intervals ranging from 1 to 12 weeks, is characteristic. Disease onset is nearly always prior to age 15 months, with a male-to-female ratio of 4:1. It differs from eosinophilic folliculitis in adults by primarily involving the scalp, frequently developing secondary crusting, and the lack of an annular configuration. Although there can be some clinical overlap, the hands and feet are the primary sites of involvement in infantile acropustulosis.

This disorder is currently viewed as a reaction pattern to a variety of triggers such as arthropod bites. Histologically, there is eosinophilic spongiosis as well as clusters of eosinophils and neutrophils within the hair follicle, especially its infundibular region. A perifollicular mixed inflammatory infiltrate can also be seen. The disease is benign and self-limited, with the majority of children experiencing resolution by 3 years of age. Topical corticosteroids can be used for relief of pruritus.

Disseminate and Recurrent Infundibulofolliculitis

Synonyms: ■ Hitch and Lund disease ■ Recurrent disseminated infundibulofolliculitis

Key features
- Seen primarily in young adults with darkly pigmented skin
- Numerous uniform, skin-colored papules that have been likened to "goose bumps"
- Favored sites of involvement are the trunk, neck, and upper extremities
- May last for months to years and can be pruritic
- Histologically, there is perifollicular edema and a mild inflammatory infiltration of lymphocytes within the follicular infundibulum

Downloaded for Anonymous User (n/a) at Egyptian Knowledge Bank from ClinicalKey.com by Elsevier on March 10, 2024. For personal use only. No other uses without permission. Copyright ©2024. Elsevier Inc. All rights reserved.

Disseminate and recurrent infundibulofolliculitis (DRIF) was first described by Hitch and Lund in 1968[15]. Most affected individuals have skin phototypes V or VI. DRIF is characterized by numerous 1–2 mm, pruritic, skin-colored, folliculocentric papules. Parallel rows of lesions correspond to the distribution pattern of hair follicles. The trunk is involved most often, followed by the neck, buttocks, and arms. The lesions may last for weeks, months, or years.

DRIF most closely resembles papular eczema, which also favors darker skin phototypes. Other diseases in the differential diagnosis include lichen nitidus and folliculitis (see above), but the follicular pattern and the lack of erythema or pustules exclude these two entities, respectively. The lack of keratotic plugs or spines within the hair follicles distinguishes this disorder from keratosis pilaris, pityriasis rubra pilaris (PRP), lichen planopilaris, and the disorders discussed in the next section (e.g. phrynoderma).

Although low serum vitamin A levels have been reported[16], the etiology remains unclear. Histologically, the principal findings are in the infundibular portion of the hair follicle. There is perifollicular edema and a slight infiltration of lymphocytes with occasional neutrophils[17]. Spongiosis of the follicular epithelium is usually absent or minimal.

Topical corticosteroids may provide symptomatic relief and lactic acid preparations (12%) or 20% urea may be helpful. If topical medications prove unsuccessful, doxycycline, vitamin A (50 000 IU twice daily), isotretinoin (0.5 mg/kg/day for 16 weeks), and PUVA (with twice monthly maintenance) have also been tried with mixed results.

DISORDERS OF FOLLICULAR KERATINIZATION

Although this group of dermatoses has a wide spectrum of clinical presentations, all are characterized by a prominent plug of keratin within the follicular orifice. For most of these entities, the cause of the abnormal keratinization is unknown. The dermatoses are usually distinguished on the basis of the size, extent, and distribution of the keratotic lesions, as well as the presence or absence of perifollicular erythema and associated scarring. Disorders in this group that are discussed in other chapters include keratosis pilaris (Ch. 12), PRP (Ch. 9), and lichen planopilaris (Ch. 11).

Erythromelanosis Follicularis Faciei

Synonym: ▪ Erythromelanosis follicularis faciei et colli

Key features

- An uncommon disorder that involves the lateral cheeks and sometimes the neck
- Multiple tiny follicular papules are superimposed on a red–brown patch; the papules often appear relatively hypopigmented
- May be accompanied by keratosis pilaris

Introduction

Erythromelanosis follicularis faciei was first described in 1960 by Kitamura and associates in Japanese men. It can begin during the second decade of life and is characterized by background erythema and hyperpigmentation as well as tiny follicular papules.

Epidemiology and Pathogenesis

Although the disorder was initially reported in Japanese men, it is now known to affect all races and both sexes[18]. However, the literature suggests it favors people of Asian ancestry. The pathogenesis is unknown.

Clinical features

Erythromelanosis follicularis faciei typically involves the lateral cheeks, including the preauricular area, with extension onto the neck. Involvement of the eyebrows, chin, submandibular region, and pinnae has also been described[18]. Numerous pinhead-sized follicular papules, which appear relatively hypopigmented, are superimposed on reddish-brown patches. The latter are due to a combination of vasodilation and hyperpigmentation, and by dermoscopy blue–gray peppering is seen with a reddish-brown background, along with an appreciation of keratotic follicular plugs[19]. In skin type I patients, there may be only erythema, leading to significant overlap with keratosis pilaris rubra. Patients may also have keratosis pilaris of the upper outer arms (see Ch. 12).

Pathology

There is slight follicular hyperkeratosis with increased epidermal pigmentation. Diameters of the hair shafts and outer root sheaths are decreased, as is the thickness of the inner root sheath. The adnexa are often surrounded by a lymphocytic infiltrate. Both the thickness and the compactness of the horny layer are usually increased. By quantitative histopathology, an increase in the percent area of superficial blood vessels was observed which correlated with visual grading of the associated erythema[20].

Differential diagnosis

The differential diagnosis of erythromelanosis follicularis faciei includes keratosis pilaris rubra as well as a combination of melasma plus telangiectatic erythema from photodamage (poikiloderma of Civatte). However, the former lacks hyperpigmentation and favors children, and while the telangiectasias in poikiloderma spare the perifollicular skin thus creating "hypopigmented" follicular papules, follicular hyperkeratosis is absent.

Less often, two disorders within the spectrum of keratosis pilaris atrophicans, ulerythema ophryogenes and atrophoderma vermiculatum, may be considered (Table 38.2). Although ulerythema ophryogenes is characterized by small follicular papules, they are erythematous, usually appear during early childhood, and favor the eyebrows. In addition, there is associated follicular atrophy and scarring alopecia of the lateral eyebrows. Atrophoderma vermiculatum affects the cheeks but presents with honeycomb scarring or a worm-eaten appearance (see Ch. 99).

Treatment

Various topical keratolytic agents have been tried, including urea cream (10%–20%), ammonium lactate lotion (6%–12%), tretinoin cream (0.025%–0.1%), adapalene (0.1%–0.3%), and an ammonium lactate plus hydroquinone (4%) cream combination. In a series of 11 patients, topical tacalcitol ointment (daily for 12 weeks) reduced roughness and scaling, but had a limited effect on facial erythema[21]. Both salicylic acid peels (20%–30%) and glycolic acid peels have been employed. When severe, limited courses of isotretinoin (0.1–1 mg/kg/day) have been tried. Laser treatment of the background erythema and/or hyperpigmentation may be attempted, but it requires multiple sessions. In a split-face study (n = 12), >50% improvement in the treated side was observed in five patients following five treatments with 585 nm PDL plus 1064 nm Nd:YAG lasers[22].

Keratosis Pilaris Atrophicans

Keratosis pilaris atrophicans encompasses a group of disorders in which the abnormality in follicular keratinization is accompanied by atrophy and scarring alopecia. The key features of ulerythema ophryogenes, atrophoderma vermiculatum, keratosis follicularis spinulosa decalvans, and folliculitis spinulosa decalvans are outlined in Table 38.2. Treatment with keratolytics, topical retinoids, topical or intralesional corticosteroids, oral antibiotics, and phototherapy has limited efficacy, but combination therapy may benefit individual patients and, anecdotally, oral retinoids, pulsed dye laser, and intense pulsed light have been reported to lead to improvement. In later stages, laser resurfacing, dermabrasion, and/or dermal fillers may help to improve the appearance of atrophic scarring.

Lichen Spinulosus

Synonyms: ▪ Keratosis spinulosa ▪ Keratosis follicularis spinosa (of Unna)

Key features

- Clusters of multiple follicular papules, each with a central keratotic spine
- Texture likened to that of a nutmeg grater
- Usually asymptomatic, arises suddenly, and enlarges over a week
- Appears most often in children and adolescents; favors the neck, extensor arms, abdomen, and buttocks
- Can persist indefinitely

Downloaded for Anonymous User (n/a) at Egyptian Knowledge Bank from ClinicalKey.com by Elsevier on March 10, 2024. For personal use only. No other uses without permission. Copyright ©2024. Elsevier Inc. All rights reserved.

THE SPECTRUM OF KERATOSIS PILARIS ATROPHICANS							
Disorder	**Mode of inheritance**	**Gene/ genetic locus**	**Age at onset**	**Distribution**	**Cutaneous features**	**KP***	**Other occasional features and associations**
Keratosis pilaris atrophicans faciei (ulerythema ophryogenes)	AD ≫ AR	18p11.2 (AD) *LRP1* (AR)	Infancy	Eyebrows, particularly the lateral third > temples, cheeks, forehead (Fig. 38.7)	• Skin-colored to erythematous follicular papules with central keratotic plugs, eventuating in follicular atrophy • Scarring alopecia of the lateral eyebrows	+	• Associated with Noonan syndrome, cardio-facio-cutaneous syndrome, monosomy 18p, woolly hair, and Swyer and Cornelia de Lange syndromes
Atrophoderma vermiculatum (see Ch. 99)	?AD	?	Childhood (usually between 5 and 12 years)	Cheeks (see Fig. 99.8) upper lip, forehead, ears	• Pitted, atrophic depressions in a vermiculate pattern ("worm-eaten" or "honeycomb" appearance)†	–	• Associated with Loeys–Dietz, Rombo, and Nicolau–Balus syndromes • Unilateral form has been associated with ipsilateral congenital cataract
Keratosis follicularis spinulosa decalvans, X-linked (KFSDX)	XLR	*MBTPS2*‡	Childhood (inflammation often remits at puberty)	Scalp, face, limbs, trunk	• Erythematous follicular papules with central keratotic plugs, eventuating in follicular atrophy • Scarring alopecia of the scalp, eyebrows, and eyelashes • Facial erythema • Palmoplantar keratoderma • Nail dystrophy (e.g. thickening, crumbling)	++	• Keratitis, blepharitis, corneal dystrophy, photophobia
Keratosis follicularis spinulosa decalvans (folliculitis spinulosa decalvans)	AD	?	Childhood; exacerbation after puberty	Scalp, face > trunk, extremities	• Compared to KFSDX: facial erythema and nail dystrophy more common; more severe scalp inflammation with pustules • Otherwise, features similar to KFSDX	++	• Blepharitis, conjunctivitis

*Associated keratosis pilaris (KP) on the extremities and trunk.
†May be preceded by erythematous keratotic follicular papules.
‡MBTPS2 (membrane-bound transcription factor peptidase, site 2) is a zinc metalloprotease required for cleavage of sterol regulatory element-binding proteins (SREBPs) and is essential for cholesterol homeostasis and the endoplasmic reticulum stress response; mutations in *MBTPS2* also underlie XLR IFAP syndrome (see Table 38.3).

Table 38.2 The spectrum of keratosis pilaris atrophicans. AD, autosomal dominant; AR, autosomal recessive; LRP1, low-density lipoprotein (LDL) receptor-related protein 1; XLR, X-linked recessive; +, mild to moderate; ++, severe.



Fig. 38.7 Ulerythema ophryogenes. Numerous skin-colored follicular papules of the lateral cheek arising within a background of erythema, along with alopecia of the eyebrows. Some of the lesions have become confluent. *Courtesy Alex Glazer, MD.*

History and epidemiology

First described by Crocker in 1883, lichen spinulosus is characterized by grouped, skin-colored, keratotic follicular papules. In one series, the average age at onset was 16 years[23].

Pathogenesis

Although several factors, such as atopy, infections and heredity, have been proposed as playing a role in lichen spinulosus, the exact etiology is unknown and most patients do not have associated systemic abnormalities. There are reports of lichen spinulosus-like lesions arising in the setting of HIV infection[24]. The terms *HIV-associated follicular syndrome* and *type VI PRP* have been proposed to encompass the constellation of HIV infection, nodulocystic acne, and lesions with follicular spines, including PRP and lichen spinulosus. Additional (likely coincidental) associations reported in the literature include seborrheic dermatitis, a drug reaction (omeprazole), Hodgkin lymphoma, Crohn disease, syphilis, and an id reaction to fungal infections.

Clinical features

Typical lesions measure 2–6 cm in diameter (Fig. 38.8) and are composed of grouped skin-colored, keratotic follicular papules, each of which has a central horny spine. Lichen spinulosus favors the neck, shoulders, and extensor surfaces of the arms, as well as the abdomen, buttocks, and popliteal fossae, and the distribution pattern may be symmetric. The hands and feet are usually spared. Lesions often arise suddenly in crops, enlarge over a week, and then remain stationary. Idiopathic lichen spinulosus usually appears during childhood and adolescence and is sometimes pruritic. Spinulosis of the face (tiny follicular keratotic spicules of the cheeks) may be a manifestation of lichen spinulosus.

Pathology

Histologically, lichen spinulosus most resembles keratosis pilaris, with follicular plugging of the infundibulum and a mild perivascular and perifollicular lymphocytic infiltrate in the upper dermis.

Differential diagnosis

The differential diagnosis of lichen spinulosus includes phrynoderma, keratosis circumscripta, follicular ichthyosis, and juvenile pityriasis

Downloaded for Anonymous User (n/a) at Egyptian Knowledge Bank from ClinicalKey.com by Elsevier on March 10, 2024. For personal use only. No other uses without permission. Copyright ©2024. Elsevier Inc. All rights reserved.

rubra pilaris (Table 38.3), in addition to folliculotropic mycosis fungoides[29]. Facial spines can also be seen in the setting of HIV-associated follicular syndrome (see above), viral-associated trichodysplasia, demodicosis, follicular mucinosis, and in patients with multiple myeloma. Lastly, widespread follicular plugging has been reported as a side effect of BRAF inhibitors and systemic lithium therapy.

Treatment

Topical therapies such as lactic acid, urea, and salicylic acid may improve the texture. There are case reports of successful treatment with adapalene gel, tacalcitol cream[30], glycolic acid peels, and tretinoin gel plus hydroactive adhesive applications[31].

Phrynoderma

Phrynoderma, which means "toad skin", is rarely seen in developed countries, except in settings such as intestinal malabsorption due to bariatric surgery and malnutrition from anorexia nervosa or fad diets (see Ch. 51). Phrynoderma is seen most often in association with vitamin A deficiency, but some patients may have measurable deficiencies in other vitamins and/or proven malnutrition[32]. Skin-colored to hyperpigmented acuminate follicular papules with central keratotic plugs favor the extensor surfaces of the extremities (see Fig. 51.7). Lesions of the face, hands, or feet would be unusual to rare[33]. Associated systemic findings (e.g. ocular, CNS), histologic features, diagnosis via measurement of serum vitamin A levels, and treatment are discussed in Chapter 51.



Fig. 38.8 Lichen spinulosus. Grouped, skin-colored follicular papules on the extensor surface of the arm. Central keratotic plugs can be seen.

TRICHOSTASIS SPINULOSA

Trichostasis spinulosa is a common, but often underdiagnosed, follicular disorder of unknown etiology. Comedo-like lesions that contain keratin and multiple vellus hairs are seen, primarily on the mid to lower central portion of the face, including the nose (see Table 36.2). Lesions can develop on the trunk, most commonly the interscapular region, and less often the axillae and scalp, including within an isolated collagenoma[34] and after application of minoxidil[35]. The differential diagnosis is outlined in Table 36.2. Histologically, within a dilated hair follicle, there are multiple, small vellus hairs and keratinous debris; a perifollicular, mild mixed inflammatory infiltrate may be present. Therapeutic options include keratolytics, topical tretinoin, depilatories, adhesive strips, and lasers (e.g. long-pulsed alexandrite, short-pulsed alexandrite, pulsed diode).

VIRAL-ASSOCIATED TRICHODYSPLASIA SPINULOSA

Synonyms: ■ Viral-associated trichodysplasia ■ Viral-associated trichodysplasia of immunosuppression ■ Trichodysplasia spinulosa

Viral-associated trichodysplasia (see Ch. 81) is associated with drug-induced immunosuppression, most often in organ transplant recipients, and it reflects infection with the *t*richodyplasia *s*pinulosa-associated *p*oly*o*ma*v*irus (TSPyV)[36] (see Ch. 81). The virus' small T antigen may play a role in disrupting the cycling of follicular keratinocytes[37]. Skin-colored to

DIFFERENTIAL DIAGNOSIS OF LICHEN SPINULOSUS	
Keratosis circumscripta[25–27] (psoriasis circumscripta with palmoplantar keratosis)	• Age at onset usually 3–5 years and described primarily in Africans • Well-circumscribed lesions consisting of grouped folliculocentric papules, with or without palmoplantar hyperkeratosis • Lesions favor the elbows and knees, neck, hips, sacrum, and posterior axillary folds • Some authors argue that this is a variant of psoriasis as the histologic findings are similar to those of plaque-type psoriasis
Follicular ichthyosis[28]	• Onset during early childhood • Keratotic papules with follicular plugging and prominent follicular ostia • Favors the head and neck region, but may also involve the extensor surfaces of the extremities, especially the fingers, elbows, and knees
Ichthyosis follicularis with atrichia and photophobia (IFAP) syndrome (Ch. 57)	• XLR (*MBTPS2* mutations, allelic with keratosis follicularis spinulosa decalvans; see Table 38.2) or AD (*SREBF1* mutations) • In female carriers, linear streaks consisting of follicular keratoses, scaling, and/or hypotrichosis • In affected males, generalized congenital non-scarring alopecia, photophobia, follicular keratoses, and psoriasiform plaques (see Fig. 55.11)
Hereditary mucoepithelial dysplasia	• AD with more widespread follicular keratoses and non-scarring alopecia (similar to IFAP; also *MBTPS2* mutations) • Severe keratitis, erythema of the oral mucosa (paucity of desmosomes and dyskeratotic cells histologically), and psoriasiform plaques that favor intertriginous zones, especially the perineal area
Juvenile pityriasis rubra pilaris (Ch. 9)	• Especially type IV (circumscribed), in which lesions favor the elbows and knees
Keratosis pilaris (Ch. 12)	• Perifollicular erythema in addition to follicular plugging • Favors the upper outer arms and the thighs, but lacks discrete clusters • May be more widespread in keratosis pilaris-like drug eruptions (e.g. sorafenib)
Lichen planopilaris (Ch. 11)	• Follicular keratotic plugs are surrounded by a narrow violaceous rim • Scarring alopecia of the scalp most common presentation but follicular lesions may be disseminated
Folliculotropic mycosis fungoides (Ch. 120)	• Acneiform lesions may be seen, including comedones (see Fig. 36.16B,C); they may be clustered
Phrynoderma (vitamin A deficiency; Ch. 51)	• Follicular papules with a central keratotic plug favor the extensor surfaces of the extremities and buttocks • Generalized xerosis, sparse fragile hair, night blindness, xerophthalmia

Table 38.3 Differential diagnosis of lichen spinulosus. Viral-associated trichodysplasia is discussed in the text and Chapter 81. The differential diagnosis also includes the spinous variant of lichen nitidus and follicular keratosis (of the chin). AD, autosomal dominant.

Downloaded for Anonymous User (n/a) at Egyptian Knowledge Bank from ClinicalKey.com by Elsevier on March 10, 2024. For personal use only. No other uses without permission. Copyright ©2024. Elsevier Inc. All rights reserved.

pink follicular papules and follicular spines favor the central face (see Fig. 81.16) and may be accompanied by loss of the eyebrows and eyelashes; extrafacial lesions with associated alopecia may also develop. Histologically, enlarged and distended anagen-type follicles have a high number of inner root sheath cells with excessive amounts of trichohyaline granules. If immunosuppressive therapy cannot be reduced, topical cidofovir or tazarotene gel or oral valganciclovir (900 mg once or twice daily) may be helpful.

DEEP FOLLICULITIS

The major forms of deep folliculitis are furuncles (see Ch. 74), sycosis (barbae [see Fig. 38.3B], lupoid, mycotic [Fig. 38.9]; Table 38.4), pseudofolliculitis barbae, acne keloidalis, and hidradenitis suppurativa. The lesions are firm, tender, erythematous papules or nodules. Deep lesions should never be manipulated (i.e. squeezed) by the patient, because this may cause bacteremia or seeding of the heart valves (endocarditis), brain (abscess), or bones (osteomyelitis).



Fig. 38.9 Mycotic sycosis. Firm plaque of the upper cutaneous lip studded with multiple pustules due to a zoophilic dermatophyte. *Courtesy Kalman Watsky, MD.*

FORMS OF SYCOSIS	
Type	**Characteristics**
Barbae	• Bacterial folliculitis of the beard and/or mustache areas, usually caused by *Staphylococcus aureus* • Deep-seated, edematous, perifollicular papules and pustules that may coalesce to form crusted plaques studded with pustules (see Fig. 38.3B) • Subacute to chronic course with frequent relapses
Lupoid	• Scarring form of deep folliculitis, typically affects the beard area; may be caused by *S. aureus* (although cultures often fail to reveal pathogenic organisms) • Peripheral extension of perifollicular papules and pustules with central scarring alopecia; appearance can be reminiscent of lupus vulgaris • Chronic course, refractory to treatment
Mycotic	• Dermatophyte folliculitis of the beard area, usually caused by zoophilic organisms • Inflammatory perifollicular papules and pustules coalesce to form nodules and plaques with crusts, purulent discharge from patulous follicles, and loose hairs that can be painlessly removed (Fig. 38.9)
Herpetic	• See Table 38.1

Table 38.4 Forms of sycosis. Sycosis is defined as chronic inflammation of hair follicles, especially of the beard.

Pseudofolliculitis Barbae

Synonyms: ■ Shave bumps ■ Razor bumps ■ Barber's itch ■ Folliculitis barbae traumatica ■ Scarring pseudofolliculitis of the beard ■ Chronic sycosis barbae ■ Ingrown hairs

Key features

- A common chronic disorder occurring most often in the beard area of men who shave
- It favors Black men with tightly curled hair
- Distal tips of hairs curve back into the skin after having been shaved
- Lesions range from inflammatory papules and pustules to firm papules and keloidal scars
- Although the only reliable way to cure the disease is to stop shaving, shaving techniques can be optimized and laser therapy can significantly reduce severity

Introduction

Pseudofolliculitis barbae is a common chronic inflammatory disorder of terminal hair-bearing sites, occurring most often in the beard area of men who shave and have tightly curled hair.

Epidemiology

Although pseudofolliculitis barbae can occur in any racial group, it primarily affects Black men. The incidence in African-American men varies from 45%–85%, depending upon the particular study. Pseudofolliculitis barbae is less common and is usually milder in those with straight hair. Women may also develop pseudofolliculitis following shaving or plucking of hairs in the groin, axillae, or a hirsute face.

Pathogenesis

The disorder is thought to be caused by re-entry of the distal portion of tightly curled hairs into the skin. In individuals with tightly curled hair, the hair follicles sit at an oblique angle and when shaved, a sharp tip is created at the distal end of the hair. Fig. 38.10 illustrates extrafollicular and transfollicular forms of hair penetration. Once the hair penetrates the dermis, an inflammatory reaction ensues.

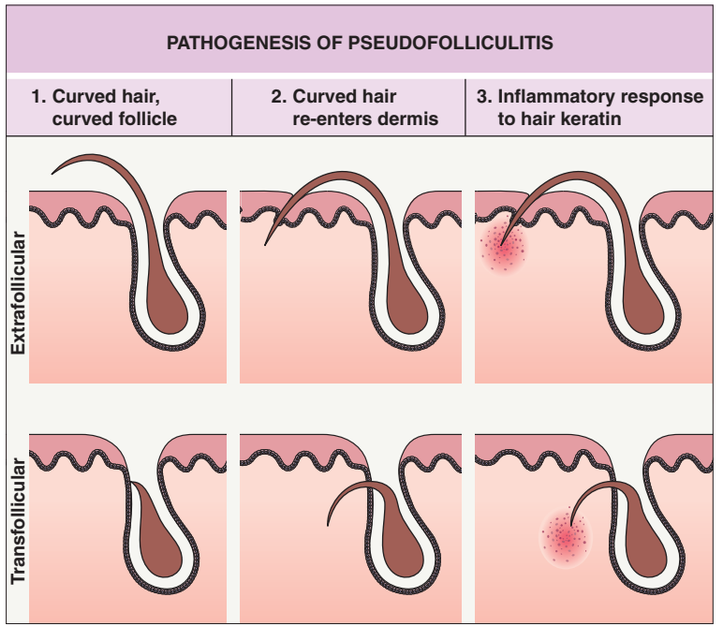

Fig. 38.10 Pathogenesis of pseudofolliculitis. In individuals with tightly curled hair, the hair follicles sit at an oblique angle and when shaved, a sharp tip is created at the distal end of the hair. There are two proposed mechanisms for hair penetration: (1) *extrafollicular* – the cut hair grows normally from the follicular orifice but then curves downward and penetrates the skin surface 1–2 mm distally from where the hair exits; and (2) *transfollicular* – the distal tip of the cut hair shaft pierces the follicular epithelium and penetrates the dermis instead of normally exiting the follicular orifice. *Courtesy M. A. Abdallah, MD.*

Downloaded for Anonymous User (n/a) at Egyptian Knowledge Bank from ClinicalKey.com by Elsevier on March 10, 2024. For personal use only. No other uses without permission. Copyright ©2024. Elsevier Inc. All rights reserved.

The presence of a single nucleotide polymorphism in the 1 A α-helical subdomain of the hair follicle companion layer-specific keratin K6hf (KRT75) has been reported to be an additional genetic risk factor for pseudofolliculitis barbae[38]. In women, hyperandrogenism may be a contributing factor[39].

Clinical features

Skin-colored to red-brown papules or pustules develop in hair-bearing sites that have been shaved (Fig. 38.11). These lesions are most commonly observed within the beard area. Postinflammatory hyperpigmentation and scarring, including keloid formation, are potential sequelae. Chronic lesions may cause the hair to create grooves in the skin; the anterior neck and submandibular areas are particularly prone to this complication. Once the grooves have formed, shaving becomes extremely difficult.



Fig. 38.11 Pseudofolliculitis barbae. Multiple firm hyperpigmented papules on the lower face and neck (beard distribution). *Courtesy Paul Kelly, MD.*

Pathology

The sharp cut end of the hair initially causes an invagination in the epidermis, which is accompanied by inflammation and frequently by an intralesional microabscess. As the hair penetrates the epidermis, a heavy mixed inflammatory cell infiltrate develops as a reaction to the downgrowth of the epidermis in an attempt to ensheathe the hair[40]. This is accompanied by abscess formation within the pseudofollicle and a foreign body giant cell reaction at the tip of the invading hair. Naked hair shafts surrounded by acute and chronic inflammation or a primarily fibrotic dermis are commonly observed.

Differential diagnosis

Facial acne vulgaris is similar in appearance, but differs by having open or closed comedones and a distribution beyond the beard region. In sycosis barbae, which also commonly occurs in the beard region, the lesions tend to be more confluent rather than discrete. Histologically, the foreign body reaction needs to be differentiated from cutaneous sarcoidosis.

Treatment

Before therapy is initiated, the patient should be given a candid explanation regarding the cause of pseudofolliculitis barbae. It should be stressed that the only reliable way to cure the disease is to stop shaving, but there are several treatments that may control the process, including laser therapy. In those with severe disease, a hiatus of several months without shaving is recommended. When patients resume shaving once the inflammatory lesions have completely cleared, they need to be given advice on shaving methods (Table 38.5).

Except for very mild cases, pseudofolliculitis barbae requires medical intervention during its acute phase, when it is often painful and/or pruritic.

THERAPEUTIC APPROACH TO PSEUDOFOLLICULITIS BARBAE	
Advice on shaving methods	
Important points	
• Do not pull the skin taut • Use a sharp razor each time (single-edged with protective foil preferred*) or an electric razor • Take short light strokes and do not shave over the same areas more than twice • For severe disease: discontinue shaving until all inflammatory lesions have cleared and all "ingrown hairs" are released; during this period, the patient can trim beard to a minimum length of 5 mm using scissors or electric clippers	
Method	
• Remove pre-existing hairs with electric clippers, leaving approximately 1–2 mm of stubble (only step if this length is acceptable to the patient) • Wash area with warm water, non-abrasive soap, and a soft brush or sponge • Rinse area with warm water or apply warm compress • Using shaving cream, massage moderate amount of lather on area to be shaved 5–10 minutes prior (do not allow lather to dry; if it does, reapply it) • Use a sharp blade* and shave the hair using short even strokes with minimal tension (and no more than twice over one area) • Traditionally, patients were advised to shave in the direction of hair growth ("with the grain"), but shaving against the grain may not worsen the disease[41] • After shaving, rinse with tap water and then apply a soothing aftershave preparation. If significant burning or itching ensues, apply a topical corticosteroid cream or lotion (1%–2.5% hydrocortisone)	
Treatment recommendations	
Compresses	• Warm tap water, saline, or Burow's solution (aluminum acetate) compresses for 10 minutes three times daily to soothe lesions, remove any crusts, reduce drainage secondary to inflammation and/or excoriations, and soften the epidermis to allow easier release of "ingrown hairs"
Topical and intralesional therapy	• Low-potency topical corticosteroid lotion, topical antibiotics (e.g. clindamycin), and/or topical retinoids should be applied after compresses and freeing of embedded hairs • Topical glycolic acid 8% lotion • Intralesional triamcinolone acetonide injections (5–10 mg/ml)
Secondary bacterial infection	• Appropriate systemic antibiotic should be prescribed, based upon bacterial cultures
Recalcitrant disease	• Topical eflornithine cream twice daily may be helpful† • Laser hair removal (utilizing appropriate laser for skin color) with goal of permanent hair reduction (see Ch. 137)
Postinflammatory hyperpigmentation	• Hydroquinone ± topical retinoids and corticosteroids, azelaic acid, kojic acid • Chemical peels (see Ch. 154)
*However, in one study, there was no difference in disease activity between single- versus multi-blade razors[72]. †Based upon case series.	

Table 38.5 Therapeutic approach to pseudofolliculitis barbae. *Courtesy A. Paul Kelly, MD.*

Downloaded for Anonymous User (n/a) at Egyptian Knowledge Bank from ClinicalKey.com by Elsevier on March 10, 2024. For personal use only. No other uses without permission. Copyright ©2024. Elsevier Inc. All rights reserved.

Although antibiotics, topical or systemic, are not particularly beneficial (unless secondary infection is present), they may provide some anti-inflammatory effect. The recommended therapeutic approach is outlined in Table 38.5. Adjunct treatments such as topical keratolytics (e.g. retinoids, α-hydroxy acids) and benzoyl peroxide washes may be used in patients with mild to moderate pseudofolliculitis barbae. However, those with severe and chronic disease usually have only slight improvement with these therapies.

Laser hair removal can lead to a significant reduction in disease severity. For example, the 1064 nm Nd:YAG laser can be used with a long pulse duration and continuous contact cooling, even in patients with skin types V or VI, as can a modified 810 nm super-long-pulsed diode laser. Treatment is given at 3- to 4-week intervals for two to three sessions. Care must be taken when selecting the laser fluence, especially in patients with darkly pigmented skin[42]. Additional therapeutic options are chemical depilatories and eflornithine cream; application of eflornithine cream twice daily between laser hair removal sessions led to better outcomes when compared with laser alone[43]. Prior to application of chemical depilatories, the beard should be trimmed and, to avoid irritation, treatments should be limited to twice weekly.

Acne Keloidalis

Synonyms: ■ Acne keloidalis nuchae ■ Folliculitis keloidis nuchae ■ Nuchal keloid acne ■ Folliculitis keloidalis ■ Dermatitis papillaris capillitii (historical)

Key features

- Begins as inflamed follicular papules or pustules on the posterior neck and occipital scalp
- With time, keloidal papules and plaques develop
- Vast majority of affected individuals are Black men

Introduction

Acne keloidalis refers to the presence of keloid-like papules and plaques on the occipital scalp and posterior neck. This disorder occurs primarily in Black men. The patients usually develop a chronic folliculitis and perifolliculitis of the posterior scalp and neck, which then heals with keloid-like papules. Over time, these papules may coalesce to form one or several large plaques, which gradually enlarge over a period of years. The lesions are usually pruritic and may also be painful and cosmetically disfiguring. Early intervention may prevent progression to disfiguring disease.

History

The disorder was first described by Hebra in 1860 as "sycosis framboesiformis". In 1869, Kaposi termed it "dermatitis papillaris capillitii". Three years after Kaposi's publication (1872), Bazin named the condition "acne keloidalis".

Epidemiology

In the US, acne keloidalis occurs most often in African-American men. Acne keloidalis may also occur in women, but the male:female ratio is at least 20:1. Development prior to puberty or after the age of 55 years is rare. An association with metabolic syndrome[44] and hidradenitis suppurativa has been observed in population-based studies.

Pathogenesis

The cause of acne keloidalis is unknown, and no specific genetic factor has been identified. Histologically, fragments of naked hair shafts, surrounded by microabscesses and/or granulomatous inflammation, can be seen within a fibrotic dermis[45]. A possible explanation is skin injury. In one study, the mast cell density of the neck/occipital scalp was increased compared with the anterior scalp; these mast cells may prompt rubbing and other physical manipulation of the skin, thereby predisposing this location to the development of acne keloidalis. Chronic irritation from high-collared shirts or helmets could also play a role. Perhaps acne keloidalis represents a primary form of scarring alopecia triggered by an aberrant cutaneous immune reaction[45].

Clinical features

Acne keloidalis often begins as a posterior scalp and/or neck folliculitis, followed by the development of 2–4 mm, dome-shaped, firm follicular papules that may or may not be pruritic (Fig. 38.12). Pustules may also be present within the same area but are usually short-lived because they are traumatized when the hair is combed or brushed or are easily ruptured by scratching. In contrast to acne vulgaris, comedones are not present.

As the disease progresses, more hard papules develop and slowly enlarge. Some coalesce and form keloid-like plaques, which are often arranged in a band-like distribution near the posterior hairline (Fig. 38.13). The plaques are usually only a few centimeters in diameter but may grow to more than 10 cm. Even when only papules are present, a large portion of the posterior scalp may be involved.

When the area of involvement is significant, there is usually associated patchy alopecia or complete hair loss. Occasionally, the scarring process may extend onto the vertex and/or parietal scalp. The upper borders of large lesions are often fringed with tufted hairs that resemble the hair on a doll's head, as seen in other scarring alopecias such as folliculitis decalvans (see Ch. 69). As in dissecting cellulitis, subcutaneous abscesses with draining sinuses may occasionally be present, and they may emit a malodorous discharge.



Fig. 38.12 Acne keloidalis. An admixture of follicular pustules, crusted papules and firm fibrotic hyperpigmented papules on the posterior neck and occipital scalp. There is associated alopecia.

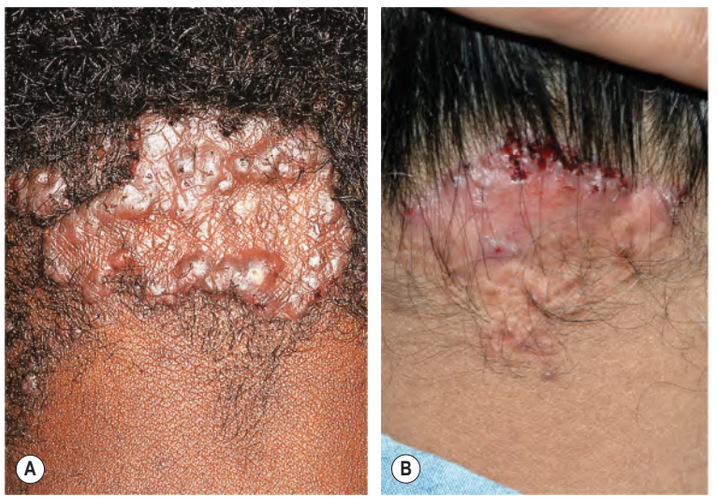

Fig. 38.13 Acne keloidalis. A Keloidal papulonodules and a large plaque of the occipital scalp, associated with scarring alopecia. Note the tufts of hair at the superior border of the scar. **B** Although the disorder is seen less often in Hispanic patients, the clinical findings are similar. *A, Courtesy Paul Kelly, MD; B, Courtesy Luis Requena, MD.*

Downloaded for Anonymous User (n/a) at Egyptian Knowledge Bank from ClinicalKey.com by Elsevier on March 10, 2024. For personal use only. No other uses without permission. Copyright ©2024. Elsevier Inc. All rights reserved.

Pathology
Inflammation begins in the upper one-third of the hair follicle. Descriptions of the initial infiltrate vary from it being composed of neutrophils and lymphocytes to predominantly plasma cells[46]. In more advanced lesions, hair follicles are disrupted, and fragments of naked hair shafts surrounded by microabscesses and/or granulomatous inflammation may be noted (Fig. 38.14). Dermal fibrosis is also present at this stage, and the collagen fibers resemble those seen in scar tissue rather than those seen in keloids. The lower portion of the follicle, including the matrix, is usually spared until later in the disease process. There is complete disappearance of sebaceous glands in late stages of the disease.

Differential diagnosis
Clinically, the initial lesions may resemble culture-negative or staphylococcal folliculitis (see above), while later-stage lesions may be mistaken for keloids or hypertrophic scars secondary to trauma. On the neck there may be overlap with pseudofolliculitis barbae, and when there is more extensive or severe scalp involvement, folliculitis decalvans and dissecting cellulitis may enter the differential diagnosis.

Treatment
Avoidance of exacerbating factors is the first line of defense. Those who have acne keloidalis should not wear any kind of head-dress or head gear that causes mechanical irritation of the posterior hairline. In addition, they should avoid wearing shirts or sweaters that irritate the posterior scalp and neck.

The sooner therapy is initiated, the less likely the patient is to develop large lesions and scarring. Twice-daily application of topical tretinoin and a mid- to high-potency corticosteroid may be sufficient to improve inflammatory papules and help flatten non-inflamed lesions. Topical or systemic antibiotics, as for acne vulgaris, may clear pustules but do not soften or clear the secondary keloidal lesions. A bacterial culture should be obtained from any site with oozing or drainage, followed by the appropriate systemic antibiotic. Triamcinolone acetonide (5–20 mg/ml) can be injected into persistent inflammatory or keloidal papules, taking into account hypopigmentation and atrophy as potential side effects.

If keloidal papules persist, they often need to be removed by a punch excision with a hair transplant trephine followed by either a primary closure or healing by second intention. The punch must extend below the level of the hair follicle to be successful. In addition, a 50:50 mixture of 2% lidocaine with epinephrine (adrenaline) and triamcinolone acetonide (40 mg/ml) may be employed for local anesthesia in order to help prevent recurrence. Excisions can be closed with silk rather than rigid sutures to prevent suture ends from piercing the surrounding skin.

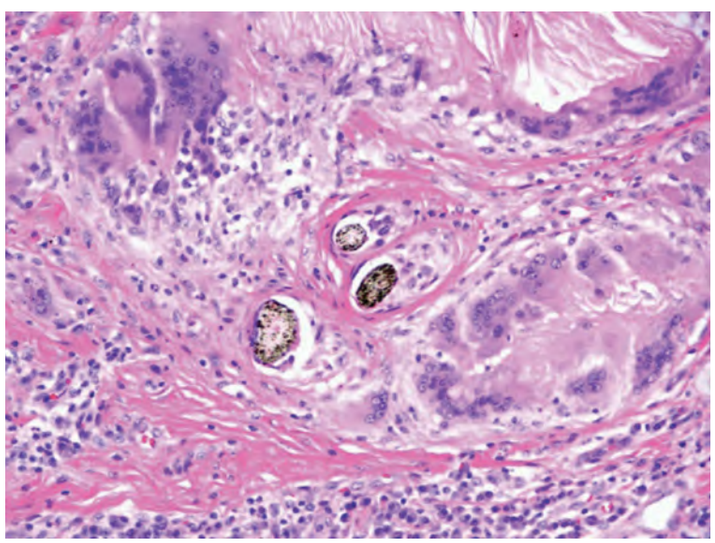

Fig. 38.14 Acne keloidalis – histopathologic features. Naked hair shafts in the dermis with perifollicular fibrosis and surrounding granulomatous inflammation with multinucleated giant cells.

For plaques 1.0–1.5 cm in vertical diameter, excision with primary closure is the treatment of choice, with the depth extending below the base of the hair follicles to reduce recurrence risk. Lesions >1.5 cm in vertical diameter should not be closed primarily because the postoperative scar usually spreads to the width of the excisional defect, producing a hairless flat scar. For these lesions, the area of acne keloidalis should be excised to the level of the fascia or deep subcutaneous tissue and left to heal by second intention. The horizontal surgical ellipse must include the posterior hairline[47], and it normally takes 8–12 weeks for the defect to close. During this healing phase, injection of corticosteroids may interfere with wound contracture. Excision with a CO_2 laser is another option and for large lesions, a staged excision.

The long pulsed Nd:YAG and diode lasers have been reported to be effective, particularly in decreasing the number of papular lesions[48]. Targeted UVB therapy was shown to decrease mean lesion count in a split-scalp comparison study of 11 patients[49]. Cryotherapy is also sometimes used, but in individuals with darkly pigmented skin, it may cause hypopigmentation. Based on case reports, a course of oral isotretinoin may prove helpful in severe recalcitrant inflammatory cases of acne keloidalis.

FOLLICULAR OCCLUSION TETRAD

In 1956, Pillsbury, Shelley and Kligman coined the term "follicular occlusion triad" for the association of acne conglobata (see Ch. 36), hidradenitis suppurativa, and dissecting cellulitis of the scalp (see Ch. 69). They proposed that the pathologic event unique to each disease was follicular hyperkeratinization[50]. In 1975, a fourth component, pilonidal sinus, was added, creating the follicular tetrad. Most commonly located within the superior portion of the natal cleft, a pilonidal sinus contains keratinous debris and often multiple hairs. There can be associated granulomatous inflammation, pustular discharge, and even abscess formation. It is also referred to as a pilonidal cyst or sacrococcygeal fistula and treatment involves surgical excision.

Hidradenitis Suppurativa

Synonyms: ■ Acne inversa ■ Verneuil disease ■ Velpeau disease ■ Apocrine acne
Advanced disease: ■ Fox-den disease ■ Pyoderma fistulans sinifica

Key features
- An inflammatory keratinization disorder characterized by follicular occlusion
- Associated with systemic inflammation, metabolic and polycystic ovary syndromes, and autoinflammatory disorders
- Predilection for intertriginous zones, especially the axillary, anogenital, and inframammary regions
- Recurrent painful inflamed nodules and abscesses; with increasing severity, formation of chronic draining tunnels, scars, and potentially squamous cell carcinoma
- Histologically, follicular dilatation and hyperkeratinization, with concomitant inflammation of the sweat glands in a minority of cases

Introduction
Hidradenitis suppurativa (HS) is a chronic cutaneous disorder that preferentially affects intertriginous skin, in particular the axillae and anogenital regions. It is characterized by recurrent inflammatory nodules and abscesses that may progress to form draining sinus tracts and scars.

History
In the 1830s, Velpeau and Verneuil conceptualized HS as a specific disease. Although apocrine gland dysfunction was initially considered to be the underlying cause, it is now believed that occlusion of the follicular

Downloaded for Anonymous User (n/a) at Egyptian Knowledge Bank from ClinicalKey.com by Elsevier on March 10, 2024. For personal use only. No other uses without permission. Copyright ©2024. Elsevier Inc. All rights reserved.

infundibula followed by follicular rupture is the inciting event, and apocrine gland involvement is secondary.

Epidemiology

In the US, the female : male ratio is 3 : 1 and African-Americans are 3–7 times more likely to be diagnosed with HS[51]. However, these statistics can vary, e.g. in South Korea the female : male ratio is 1 : 2[51]. Up to 25% of patients present prior to age 18 years ("early-onset" HS) and most commonly they are teenage girls 15–17 years of age. A prepubertal onset raises the possibility of an endocrine disorder, e.g. precocious puberty.

Pathogenesis

HS is a multifactorial inflammatory disease that is a consequence of follicular occlusion and immune dysregulation and is influenced by genetics/epigenetics, the cutaneous microbiome, and hormones.

The term *follicular occlusion* encompasses the predilection of HS for major skin folds, i.e. sites prone to friction and occlusion, as well as the follicular dilatation and hyperkeratinization that occurs microscopically. The latter is thought to be an inciting event, but actually may be a consequence of subclinical inflammation[52]. Follicular rupture, with release of keratin and bacteria into the dermis, follows comedone formation. An exuberant inflammatory response with abscess formation then ensues.

Immune dysregulation involves a host of cytokines and chemokines, including TNF, IL-1 α/β, IL-6, G-CSF, and various isoforms of IL-17[53,54]. Recruited neutrophils produce tissue damage via reactive oxygen species, proteases, and neutrophil extracellular traps (NETs); they also recruit macrophages, which produce additional proinflammatory cytokines, and activate complement (e.g. C3a, C5a). Degrading enzymes such as matrix metalloproteinases contribute to the thinning, fragility, and subsequent rupture of the follicular epithelium with generation of epithelial strands and tunnels.

Historically, a role for *genetics* was supported by up to 40%–50% of HS patients having a family history of HS[55] as well as an increased incidence of HS in patients with genetic disorders such as Dowling–Degos disease and the PASH (*p*yoderma gangrenosum, *a*cne, and suppurative *h*idradenitis) autoinflammatory disorder. More recently, mutations in one of three genes – *NCSTN, PSEN1*, or *PSENEN* – were shown to underlie inherited nonsyndromic ("pure") HS (Table 38.6)[56]. These genes encode three of the four components of the γ-secretase complex which cleaves proteins such as amyloid precursor protein and Notch. Of note, mice deficient in Notch 1 and 2 phenotypically mimic mice deficient in γ-secretase, with cyst formation and both epidermal and follicular defects, pointing to a role for the Notch cell signaling pathway in HS[57]. Additional possible candidate genes are outlined in Table 38.6[58].

Epigenetic changes include: (1) decreased expression of DNA hydroxymethylation regulators (e.g. TET1) in HS lesional skin; (2) inflammatory stage-dependent changes in expression of different microRNA (miRNA), which are involved in gene silencing via repression of mRNA translation (see Fig. 3.14); and (3) differential expression of RNA-induced silencing complex (RISC) components[58].

Regarding the *cutaneous microbiome*[59], a decreased relative abundance of skin commensal bacteria (specifically *Cutibacterium)* and an increased relative abundance of mixed anaerobic bacteria (e.g. *Prevotella, Porphyromonas*, *Peptoniphilus* spp.) have been observed in lesional skin when compared to either non-lesional or healthy control skin. Increased bacterial diversity and relative abundance of anaerobic bacteria both positively correlate with HS severity. When compared to healthy control skin, unaffected HS skin folds were also found to have an increased relative abundance of anaerobic bacteria. *Staphylococcus aureus* abundance in non-lesional skin positively correlates with overall HS clinical severity.



Fig. 38.15 Hidradenitis suppurativa. A Papulopustules, nodules, sinus tracts and scarring in the axilla (Hurley stage II). **B** Multiple tunnels and scarring in the axillary region. **C** Nodules, draining sinus tracts, and marked scarring (Hurley stage III). **D** Double-ended comedones that serve as a clue to the diagnosis, even in the absence of active disease. **E** Multiple interconnecting sinus tracts, one of which has developed granulation tissue (Hurley stage III). **F** Severe disease with inflammatory nodules, hypertrophic scarring, draining fistulae and sinus tract formation of the perianal region, buttocks, and upper thighs. This is the type of patient who is at risk for the development of squamous cell carcinoma and secondary amyloidosis. **G** Cribiform and atrophic scarring due to severe facial disease. *A, Courtesy Kalman Watsky, MD; C, Courtesy Marco Romanelli, MD; F, Courtesy A. Paul Kelly, MD.*

Downloaded for Anonymous User (n/a) at Egyptian Knowledge Bank from ClinicalKey.com by Elsevier on March 10, 2024. For personal use only. No other uses without permission. Copyright ©2024. Elsevier Inc. All rights reserved.

NONSYNDROMIC HIDRADENITIS SUPPURATIVA – ASSOCIATED GENES		
Gene	**Protein product**	**Proposed function related to HS**
Familial acne inversa (ACNINV) -1, -2, -3		
NCSTN	Nicastrin (γ-secretase complex)	Regulation of epidermal and follicular keratinocyte differentiation
*PSENEN**	Presenilin enhancer-2 (γ-secretase complex)	
PSEN1	Presenilin 1 (γ-secretase complex)	
Other genes implicated in HS pathogenesis		
TNF	Tumor necrosis factor	Promotion of inflammation
BCL2	Anti-apoptotic regulatory protein	Maintenance of homeostasis in outer root sheath cells of hair follicles
IL12Rβ1	Subunit of the IL-12 and IL-23 receptors (see Fig. 128.9D)	Regulation of T cell subset differentiation

*Allelic with Dowling–Degos disease and patients may have features of both disorders.

Table 38.6 Nonsyndromic hidradenitis suppurativa (HS) – associated genes. The fourth protein in the γ-secretase complex is anterior pharynx-defective 1. Additional implicated genes include DEFB (encodes β-defensin), *MYD88*, and *ABCC11* (affects apocrine sweat gland secretion).

COMORBIDITIES IN PATIENTS WITH HIDRADENITIS SUPPURATIVA	
Organ system	**Comorbidity**
Articular	Spondyloarthritis
Cardiovascular	Hypertension Myocardial infarction Cerebrovascular accident
Cutaneous	Acne vulgaris and acne conglobata* Dissecting cellulitis of the scalp* Pilonidal disease* Pyoderma gangrenosum
Gastrointestinal	Crohn disease Ulcerative colitis
Metabolic/endocrine	Metabolic syndrome (includes dyslipidemia, hypertension, insulin resistance; see Table 53.5) Obesity Diabetes mellitus Thyroid disease
Psychiatric	Depression Generalized anxiety disorder Suicidal ideation Substance use disorder
Reproductive	Polycystic ovarian syndrome Sexual dysfunction
Other	Smoking

*Components of follicular occlusion tetrad.

Table 38.7 Comorbidities in patients with hidradenitis suppurativa (HS).

Biofilm formation has been shown to play a role in the development of acute lesions, as well as the maintenance of chronic tunnels. The gut microbiome alterations in HS are less well characterized[60], but in smaller series findings were similar to those in patients with inflammatory bowel disease and metabolic syndrome, e.g. more abundant *Bilophila* and *Holdemania* genera and less abundant *Lachnobacterium* and *Veillonella* genera.

With regard to *hormonal factors*, there is a temporal relationship between HS onset and the rise in sex hormones during puberty. In addition, HS patients have an increased incidence of metabolic syndrome and polycystic ovary syndrome. The effect of pregnancy on HS disease activity is mixed, with women reporting improvement, no change, or exacerbation[61]. Of note, HS has been found to be a risk factor for adverse pregnancy and maternal outcomes[61a].

Clinical features

Typical lesions include comedones (including double-ended comedones; Fig. 38.15D), inflammatory papules and nodules, abscesses, tunnels (both sinus tracts and skin fistulae), and scars. Less often pyogenic granuloma-like lesions and ulcers are seen. Lesions favor major body folds including the axillae, groin, buttocks, and inframammary areas (Fig. 38.15A–C). Occasionally, the face (Fig. 38.15G), post-auricular region, neck, and trunk are involved. Initially, patients have recurrent inflammatory papulonodules and abscesses that are tender and extremely painful. Over time, tunnels (Fig. 38.15E) and scars (Fig. 38.15C,F) may develop. This can be accompanied by chronic, malodorous drainage, leading to a marked degree of frustration, embarrassment, and self-consciousness. The discharged fluid is often a mixture of serous exudate, blood and pus, in varying proportions. Of note, patients may also experience pruritus[62].

Complications include soft tissue infections, lymphedema, and scarring so severe as to lead to strictures of the urethra, anus, and rectum as well as limb contractures[63]. Rarely, squamous cell carcinoma (SCC) arises within chronic HS lesions, primarily in gluteal, perianal and perineal areas, and it has a high risk of morbidity and mortality[64]. Systemic complications include anemia, spondyloarthritis, SAPHO syndrome (see Table 25.18) and secondary AA amyloidosis with nephrotic syndrome. Depression, anxiety, sexual dysfunction, social isolation, and a limited ability, or complete inability, to work or participate in daily activities are additional psychosocial issues. Comorbidities identified in patients with HS are outlined in Table 38.7[65].

As noted previously, HS is associated with a variety of uncommon genetic and autoinflammatory disorders including Dowling–Degos disease, Down syndrome[66], KID syndrome, or PASH and its variants.

Staging and outcome measures

The three major clinical grading systems are listed in Table 38.8. While some of the scoring systems are useful for measuring outcomes, others (e.g. Hurley staging system) are less adept at capturing treatment-related changes. The Hidradenitis Suppurativa Clinical Response (HiSCR) represents a dynamic measure of the percent reduction in lesional count compared to baseline[69].

HS-associated pain can be measured using an 11-point Visual Analog Scale that ranges from 0 (no pain) to 10 (worst pain). Patient-reported outcome measurement tools[70] include: (1) Hidradenitis Suppurativa Impact Assessment (HSIA) for assessing a range of daily activities; (2) Hidradenitis Suppurativa Symptom Assessment (HSSA) tool for evaluating the burden of 9 physical symptoms, e.g. pain, drainage, tenderness, warmth, odor, pruritus; and (3) Hidradenitis Suppurativa Quality of Life (HiSQOL) scale.

Pathology

A mixed inflammatory infiltrate is present within the dermis and sometimes subcutaneous tissue along with dilated, often ruptured hair follicles and sinus tracts. Abscesses are observed in active cases[71]. Granulation tissue with inflammatory cells and occasional foreign body giant cells may be present. The sinus tracts contain inflammatory cells and keratinous debris (Fig. 38.16). In chronic disease, there is extensive fibrosis and scarring with destruction of pilosebaceous follicles and sweat glands.

Differential diagnosis

Early nodular lesions of HS may resemble acne cysts, but involvement of the face is unusual in HS as are double-ended comedones in acne; epidermoid cysts when only a few lesions are present; *staphylococcal* furunculosis; and a Bartholin cyst. Later on, a combination of inflammatory nodules, sinus tracts, and scars may resemble cutaneous infections (e.g. due to mycobacteria, *Nocardia*, *Klebsiella granulomatis*) and inflammatory disorders (e.g. cutaneous Crohn disease). Lymphedema secondary to HS should be differentiated from other causes (see Ch. 105).

Downloaded for Anonymous User (n/a) at Egyptian Knowledge Bank from ClinicalKey.com by Elsevier on March 10, 2024. For personal use only. No other uses without permission. Copyright ©2024. Elsevier Inc. All rights reserved.

THREE MAJOR GRADING SYSTEMS FOR HIDRADENITIS SUPPURATIVA
Hurley staging system

• Stage I – one or more abscesses with no sinus tract or scar formation • Stage II – one or more widely separated recurrent abscesses, with sinus tract and scar formation • Stage III – multiple interconnected sinus tracts and abscesses throughout an affected region; more extensive scarring
Sartorius grading system[67]
• Anatomical regions involved: axilla (left/right), groin (left/right), gluteal (left/right) or other region (e.g. inframammary): 3 points per region involved • Number and scores of lesions for each region: nodules = 1; fistulae = 6 • The longest distance between two relevant lesions*, i.e. nodules and fistulae, in each region: <5 cm = 1; 5–10 cm = 3; >10 cm = 9 • Are all lesions clearly separated by normal skin? In each region – yes 0/no (Hurley III) 9
International Hidradenitis Suppurativa Severity Score System (IHS4)[68]
IHS4 (points) = number of nodules × 1 + number of abscesses × 2 + number of draining tunnels × 4 Mild HS: ≤3 points Moderate HS: 4–10 points Severe HS: ≥11 points
*Or size if only one lesion.

Table 38.8 Three major grading systems for hidradenitis suppurativa (HS). A refinement of the Hurley staging system in which stages I and II are subdivided into A, B, C subtypes is also utilized. In the Revuz modification of the Sartorius grading system, five regions (axilla, breast, inguino-femoral, perianal, perineal) are scored, with additional modifications including the addition of abscesses to fistulae. The Hidradenitis Suppurativa Physician Global Assessment (HS-PGA) is a 6-point scale with scores from 0 (clear) to 5 (very severe) based upon counts of inflammatory nodules, abscesses, and draining fistulae.

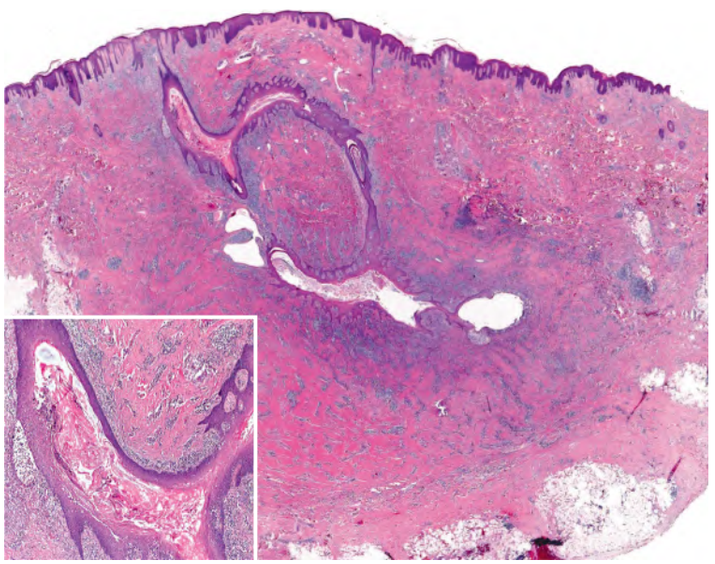

Fig. 38.16 Hidradenitis suppurativa – histopathologic features. A keratin-filled sinus tract (inset) is seen within the dermis, extending into the subcutaneous fat. It is surrounded by marked fibrosis and mixed inflammatory infiltrates. *Courtesy Lorenzo Cerroni, MD.*

Treatment

A multidisciplinary approach that addresses psychosocial issues as well as comorbidities is recommended[72–74]. A therapeutic approach to HS, based on disease severity, is outlined in Table 38.9. Individualized care is also required, e.g. a woman with pre-menstrual flares of HS may benefit from spironolactone, whereas a systemic immunomodulator may be optimal for the patient with concomitant moderate to severe HS and psoriasis (e.g. adalimumab).

Acknowledgment

The authors wish to thank the late A. Paul Kelly, MD, for his valuable contribution to this chapter in the previous editions.

Additional figures and tables on Therapeutic interventions on acne keloidalis, and Syndromic hidradenitis suppurativa and genetic disorders in which hidradenitis can be an associated finding, available in our eBook (see inside front cover for access code).

Downloaded for Anonymous User (n/a) at Egyptian Knowledge Bank from ClinicalKey.com by Elsevier on March 10, 2024. For personal use only. No other uses without permission. Copyright ©2024. Elsevier Inc. All rights reserved.

HIDRADENITIS SUPPURATIVA THERAPEUTIC LADDER	
Indication	**Therapeutic interventions**
General measures	• Discuss pain management, smoking cessation, and a healthy diet • If obese or overweight, weight reduction is recommended and may require enrollment in a weight loss program or if morbidly obese, bariatric surgery • Assess patient's mental health and refer to specialist if needed • Recommend wearing soft, breathable fabrics and loose undergarments to reduce friction and moisture • Recommend antiseptic soaps, e.g. benzoyl peroxide or chlorhexidine washes • Provide and educate patient on wound care • Consider laser hair reduction
Mild disease (Hurley stage I) (see Table 38.8)	• Intralesional triamcinolone (5–10 mg/ml) injections into inflamed lesions • Topical therapies: resorcinol, clindamycin, dapsone • Oral antibiotics*: tetracyclines (doxycycline, minocycline), clindamycin, rifampin, trimethoprim-sulfamethoxazole, metronidazole, moxifloxacin • Hormonal therapies: spironolactone, oral contraceptive pills with antiandrogenic or low androgenic progestins, metformin, finasteride • Oral retinoids (especially if patient also has cystic acne): acitretin, isotretinoin • Complementary and alternative medicine: oral zinc • Surgical treatments†; deroofing, limited local excisions

Moderate disease
(Hurley stage II)
(see Table 38.8)
	• Medical therapies for mild disease, alone or in combination with the following:
	  • Systemic immunomodulators ("biologics"): TNF inhibitors (adalimumab‡, infliximab), ustekinumab, IL-17 inhibitors[75,76,76a], IL-23 inhibitors[77,78], anakinra
	  • Other systemic immunomodulators/immunosuppressants: apremilast[79], colchicine (in combination with minocycline), cyclosporine, corticosteroids¶
	• Surgical treatments†; deroofing, local excisions, Nd:YAG laser, CO_2 laser ablation

Severe disease (Hurley stage III) (see Table 38.8)	• Medical treatments outlined for mild and moderate disease, alone or in combination with the following: • Intravenous antibiotics: ertapenem¶ • Surgical treatments†; deroofing, wide surgical excision of involved areas, CO_2 laser excision

*Combinations of oral antibiotics shown to be helpful: clindamycin + rifampin (for disease that is at least mild-to-moderate in severity) and rifampin + moxifloxacin + metronidazole (for moderate-to-severe disease); in a prospective international cohort study comparing oral tetracyclines versus clindamycin + rifampin, there was no significant difference in efficacy[74a].
†Incision and drainage is recommended only to provide acute relief for larger abscesses; it is not a definitive treatment measure given high rate of recurrence.
‡FDA-approved adult dosing regimen: 160 mg on Day 1 -or- 80 mg daily on Days 1 and 2, followed by 80 mg on Day 15 then 40 mg weekly -or- 80 mg every 2 weeks beginning on day 29. There is a weight-tiered dosing regimen for adolescents (12 years and older, weighing at least 30 kg).
¶Systemic corticosteroids may be considered for short-term rescue therapy during a severe flare, and systemic corticosteroids or intravenous ertapenem may be used as bridge therapy to a long-term therapeutic option.

Table 38.9 Hidradenitis suppurativa (HS) therapeutic ladder. Additional reported therapies include bermekimab[80], botulinum toxin A and B injections[81], JAK inhibitors[81a,81b], photodynamic therapy[82], and cryoinsufflation[83].



eFig. 38.1 Folliculitis of the leg due to *Staphylococcus aureus*. *Courtesy Luis Requena, MD.*



eFig. 38.2 Folliculitis due to *Staphylococcus aureus*. Lesions of furunculosis can also be seen. *Courtesy Kalman Watsky, MD.*



eFig. 38.3 Folliculitis of the back due to methicillin-resistant *Staphylococcus aureus*. The patient had atopic dermatitis. *Courtesy Karynne O. Duncan, MD.*



eFig. 38.4 *Pseudomonas* "hot tub" folliculitis. Edematous follicular papules on the flank that begin to develop 2–3 days following the use of a hot tub. The number and size can vary. *Courtesy Kalman Watsky, MD.*



eFig. 38.5 *Pseudomonas* "hot tub" folliculitis. Edematous follicular papules on the flank that began to develop 2–3 days following the use of a hot tub. The number and size can vary. *Courtesy Kalman Watsky, MD.*

Downloaded for Anonymous User (n/a) at Egyptian Knowledge Bank from ClinicalKey.com by Elsevier on March 10, 2024. For personal use only. No other uses without permission. Copyright ©2024. Elsevier Inc. All rights reserved.



eFig. 38.6 Dermatophyte folliculitis (Majocchi granuloma). Firm follicular papules and nodule studded with pustules within a figurate lesion of tinea. *Courtesy Joseph Chao, MD.*



eFig. 38.7 Herpetic folliculitis. The monomorphous lesions have central hemorrhagic crusts. *Courtesy Julia Pettersen, MD.*



eFig. 38.8 Herpetic folliculitis. Follicular herpes simplex viral infection in an immunocompromised host. *Courtesy Karynne O. Duncan, MD.*



eFig. 38.9 *Demodex* folliculitis. Edematous papules superimposed upon the characteristic background erythema. *Courtesy Kalman Watsky, MD.*

Downloaded for Anonymous User (n/a) at Egyptian Knowledge Bank from ClinicalKey.com by Elsevier on March 10, 2024. For personal use only. No other uses without permission. Copyright ©2024. Elsevier Inc. All rights reserved.



eFig. 38.10 Microscopic findings of follicular contents obtained via scraping of *Demodex* folliculitis. *Courtesy Joseph Chao, MD.*

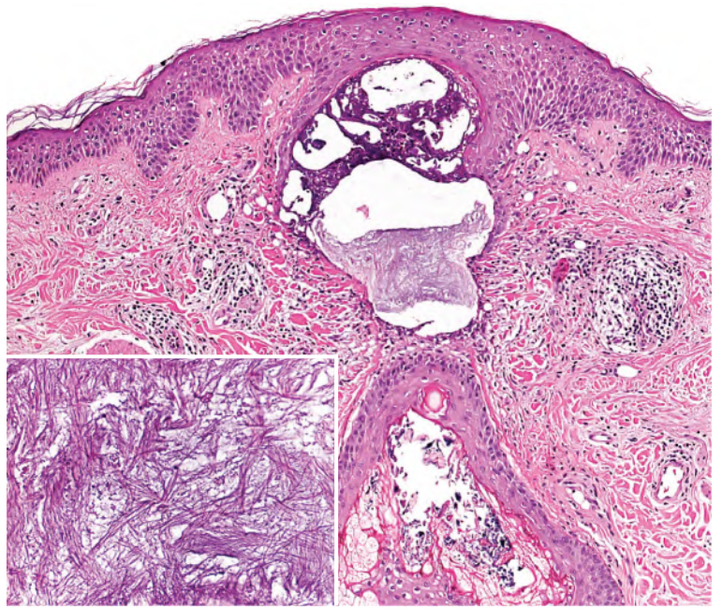

eFig. 38.12 Histopathologic features of necrotizing infundibular crystalline folliculitis. Dilated ostium of the hair follicle filled with keratin masses that show "needle-like" ("crystalline") structures. *Courtesy Lorenzo Cerroni, MD.*

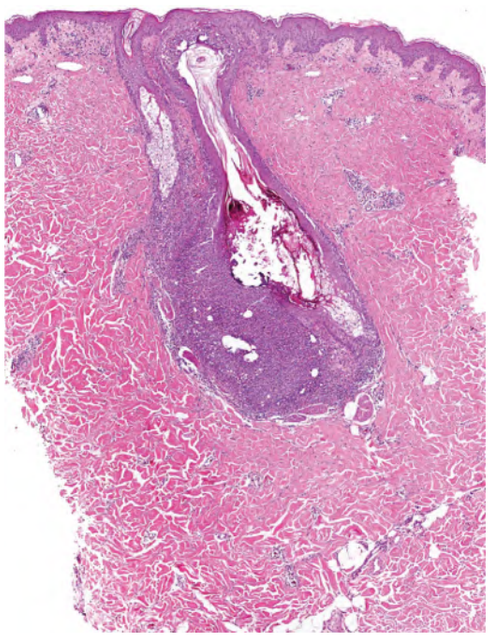

eFig. 38.11 Histopathologic features of folliculitis. Follicular and perifollicular abscess composed predominantly of neutrophils. The hair follicle is dilated and focally ruptured. *Courtesy Lorenzo Cerroni, MD.*



eFig. 38.13 *Malassezia (Pityrosporum)* folliculitis. Multiple follicular papules, some with a central pustule and others with central scale. *Courtesy Jean L. Bolognia, MD.*

Downloaded for Anonymous User (n/a) at Egyptian Knowledge Bank from ClinicalKey.com by Elsevier on March 10, 2024. For personal use only. No other uses without permission. Copyright ©2024. Elsevier Inc. All rights reserved.



eFig. 38.14 Immunosuppression-associated eosinophilic pustular folliculitis. Multiple papulopustules developed on the forehead. *Courtesy Jean L. Bolognia, MD.*

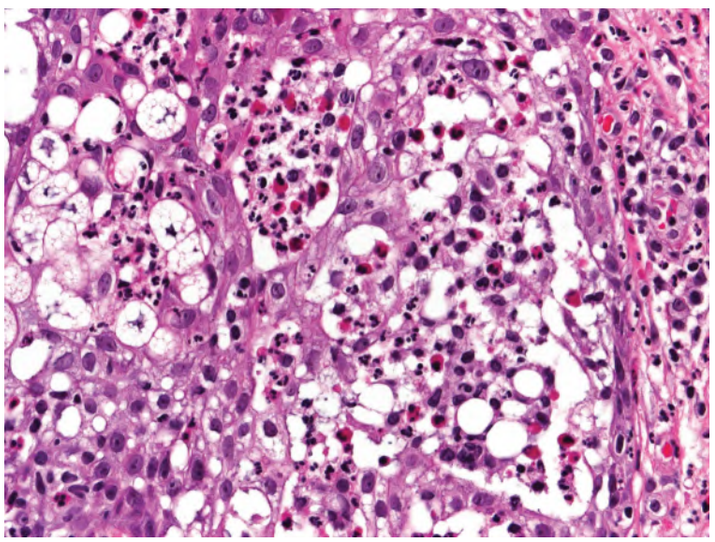

eFig. 38.15 Histopathologic features of immunosuppression-associated eosinophilic folliculitis in a patient who was HIV-positive. This hair follicle has degenerative changes and many intrafollicular eosinophils, admixed with neutrophils and lymphocytes. *Courtesy Lorenzo Cerroni, MD.*



eFig. 38.16 Disseminate and recurrent infundibulofolliculitis (of Hitch and Lund). Numerous monotonous follicular papules on the chest. *Courtesy Jean L. Bolognia, MD.*

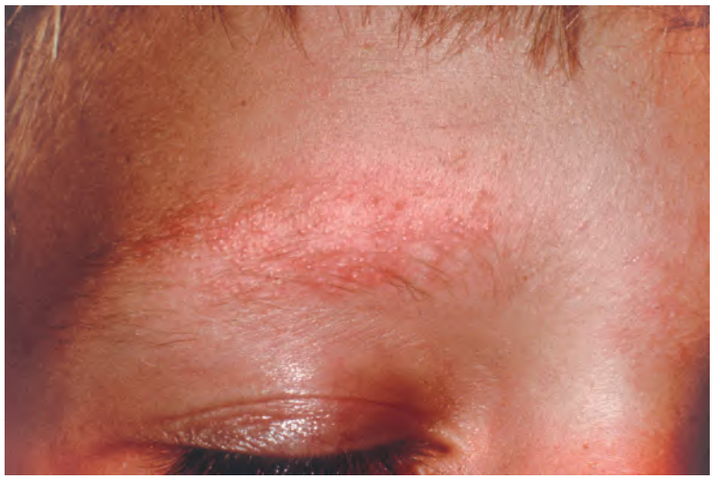

eFig. 38.17 Ulerythema ophryogenes. Alopecia of the eyebrow admixed with tiny follicular papules. *Courtesy Jean L. Bolognia, MD.*



eFig. 38.18 Ulerythema ophryogenes. Alopecia of the eyebrows on a background of erythema. *Courtesy Alex Glazer, MD.*

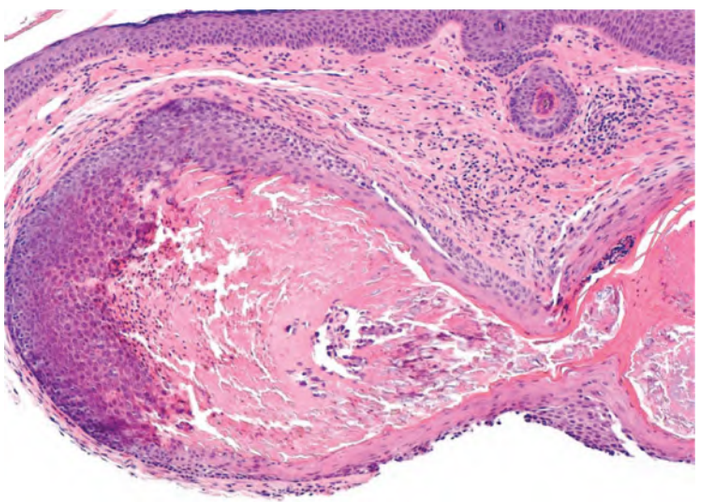

eFig. 38.19 Viral-associated trichodysplasia – histopathologic features. Dilatation and keratotic plugging of the follicle with basophilic germinative cells showing trichohyaline granules and numerous apoptotic cells. *Courtesy Leslie Robinson-Bostom, MD.*

Downloaded for Anonymous User (n/a) at Egyptian Knowledge Bank from ClinicalKey.com by Elsevier on March 10, 2024. For personal use only. No other uses without permission. Copyright ©2024. Elsevier Inc. All rights reserved.



eFig. 38.20 Pseudofolliculitis barbae. Hyperpigmented follicular papules on the neck in a woman.



eFig. 38.21 Pilonidal sinus and abscess formation at the superior portion of the intergluteal cleft. *Courtesy Kalman Watsky, MD.*

THERAPEUTIC INTERVENTIONS FOR ACNE KELOIDALIS	
Indication	**Therapeutic interventions**
Mild to moderately inflamed papules	Topical potent corticosteroid ± topical tretinoin twice daily
Inflamed lesions with pustules	Topical antibiotic (e.g. clindamycin solution) Consider bacterial culture and appropriate systemic antibiotic
	If severely inflamed, consider course of oral isotretinoin
Small keloidal papules	Topical potent corticosteroid and/or topical tretinoin twice daily
	Intralesional triamcinolone acetonide (5–20 mg/ml)
	Punch excision to a depth below the level of the hair follicles followed by either primary closure or second intention healing
	Laser hair removal for permanent hair reduction
Plaques ≤1.5 cm in vertical diameter	Excise and close primarily
Larger plaques and nodules (>1.5 cm in vertical diameter)	Excise with horizontal ellipse (include the posterior hairline)
	Extend excision to level of fascia or deep subcutaneous tissue
	Allow to heal by second intention
	Do not inject corticosteroids into postoperative site
	Laser excision is an alternative to scalpel excision

eTable 38.1 Therapeutic interventions for acne keloidalis. *Courtesy A. Paul Kelly, MD.*

Downloaded for Anonymous User (n/a) at Egyptian Knowledge Bank from ClinicalKey.com by Elsevier on March 10, 2024. For personal use only. No other uses without permission. Copyright ©2024. Elsevier Inc. All rights reserved.

SYNDROMIC HIDRADENITIS SUPPURATIVA AND GENETIC DISORDERS IN WHICH HIDRADENITIS SUPPURATIVA CAN BE AN ASSOCIATED FINDING	
Genes/chromosomes	**Encoded protein**
Syndromic hidradenitis suppurativa **– to date, genes are only implicated in pathogenesis**	
PASH and PAPASH, including variants PASS and PsAPASH	
Inflammasone activity (see Fig. 4.2)	
PSTPIP1	Proline-serine-threonine phosphatase-interacting protein 1
NLRP3	Cryopyrin
IL1RN	IL-1 receptor antagonist
MEFV	Pyrin
NFκB signaling pathway	
NOD2	Nucleotide-binding oligomerization domain-containing protein 2; plays a role in Crohn disease
Regulation of keratinocyte differentiation	
NCSTN	Nicastrin (γ-secretase complex)
Immunoproteosome component	
PSMB8	Proteosome 20S subunit beta 8
Genetic disorders in which HS can be an associated finding	
Dowling–Degos disease	
PSENEN	Presenilin enhancer-2 (γ-secretase complex)
POFUT1	Protein O-Fucosyltransferase 1
Down syndrome	
Trisomy 21	Amyloid precursor protein – competitive substrate for γ-secretase complex, along with Notch
Pachyonychia congenita (primarily steatocystomas)	
KRT6A	Keratin 6a
KRT17	Keratin 17
Familial Mediterranean fever	
MEFV	Pyrin – regulates inflammasome activity
Darier disease	
ATP2A2	Sarco/endoplasmic reticulum calcium ATPase (SERCA) 2b isoform influences folding of Notch1 receptor within SER
Keratitis–ichthyosis–deafness (KID) syndrome	
GJB2 (G12R missense mutation)	Connexin 26

eTable 38.2 Syndromic hidradenitis suppurativa and genetic disorders in which hidradenitis suppurativa can be an associated finding. HS-like lesions can develop within a nevus comedonicus. PAPASH, pyogenic arthritis, acne, pyoderma gangrenosum, suppurative hidradenitis; PASH, pyoderma gangrenosum, acne, suppurative hidradenitis; PASS, pyoderma gangrenosum, acne, suppurative hidradenitis, ankylosing spondylitis; PsAPASH, psoriatic arthritis, pyoderma gangrenosum, acne, suppurative hidradenitis.

Downloaded for Anonymous User (n/a) at Egyptian Knowledge Bank from ClinicalKey.com by Elsevier on March 10, 2024. For personal use only. No other uses without permission. Copyright ©2024. Elsevier Inc. All rights reserved.